Medical Xpress

Cell-CT: A new dimension in breast cancer research

January 5 2012, by Richard Harth

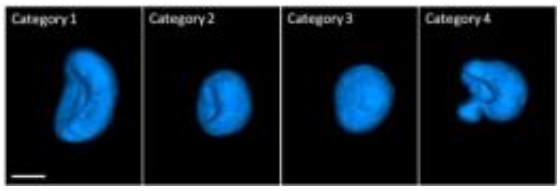

These surface shaded renderings illustrate four nuclear shape categories of human mammary epithelial cells (scale bar = 5 microns). Credit: The Biodesign Institute at Arizona State University

Despite advances in both the diagnosis and treatment of breast cancer, the disease remains a leading worldwide health concern.

Now, a new imaging technology under investigation at the Biodesign Institute at Arizona State University may help researchers pinpoint subtle aberrations in cell nuclear structure, the molecular biosignature of cancer, thus significantly improving diagnostic accuracy and prognosis by providing early detection of the disease.

The team, led by Professor Deirdre Meldrum, ASU Senior Scientist and Director of the Center for Biosignatures Discovery Automation at Biodesign has examined normal, benign and malignant cells, using the first and only research Cell-CT (VisionGate, Inc., Phoenix, AZ)—a specialized instrument capable of imaging cells in vivid 3-D with true

isotropic resolution. The technology permits the examination of subtle cellular details inaccessible by more conventional forms of microscopy that are inherently 2-D.

The group's findings appear in today's issue of the journal *PLoS ONE.*

The 3-D movie images of cells observed in the study reveal numerous telltale traces of their condition as normal or aberrant. Professor Meldrum says "there are numerous quantitative morphological parameters that are indicative of disease and may be used as biosignatures for disease staging and diagnosis. For example, a cancerous cell typically has an enlarged nucleus, nuclear invaginations, chromosome mutations, and unique nuclear shape changes."

Breast cancer remains the most common cancer in women. In 2011, an estimated 232, 000 new cases were diagnosed and some 39,000 fatalities occurred. Over a normal lifetime, 1 in 8 women will be diagnosed with the disease. In general, breast cancer begins either in the ducts of the mammary gland, (ductal carcinomas) or the lobes of the breast (lobal carcinomas).

Currently, the definitive clinical diagnosis of malignancy relies on careful examination of the nuclear structure of cells that have been prepared by histological staining and subjected to bright field microscopy. According to Vivek Nandakumar, lead author of the current study, pathologists qualitatively examine cell features including nuclear size, shape, nucleus-to-cytoplasm ratio, and the texture of cell chromatin. However, these observations do not involve quantitative measurements that would promote a more accurate analysis.

Meldrum concurs, as to the shortcomings of traditional pathology. As director of the Microscale Life Sciences Center, an NIH Center of Excellence in genomic science, she has devoted much of her career to

the close study of cell heterogeneity, and the manner in which individual cells can go awry as they transition to diseased states. "In our analysis of live single cells we can quantify significant variation from cell to cell under the same conditions," says Meldrum.

The group used Cell-CT to examine 150 cells in each of three specific categories: normal, benign fibrocystic and malignant breast epithelial. Controversy remains as to whether breast fibrosis, which may result from hormonal changes, is a normal condition or an early harbinger of malignancy. The condition occurs when ligaments, scars, supportive tissue or other fibrous tissue become more prominent in the breast than fatty tissue.

Cell-CT is a new kind of microscope, able to image cells in three-dimensions, using a technique called optical projection tomography. Cell-CT operates much like a normal CT scanner, though it uses visible photons of light, rather than X-rays. Cells prepared for observation are not placed on slides, but are instead suspended in gel and injected through a micro-capillary tube that permits multiple imaging in 360 degrees.

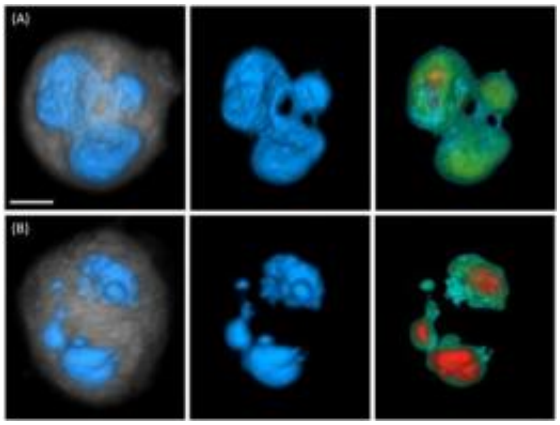

This image shows instances of irregular MDA-MB-231 nuclear morphologies (scale bar = 5 microns). Panel (A) depicts a multilobular nucleus and panel (B)

illustrates a cell with micronuclei. Left images show nuclear surface in blue and cytoplasm in gray, middle images show surface-shaded renderings of the nuclear volume, and right images depict volume renderings through the nuclear volume. Increasing nuclear density is color coded from green to red. Credit: The Biodesign Institute at Arizona State University

The scanning process produces hundreds of thin slices through the cell. These sections, or tomographs, are reassembled through computer software, forming a detailed 3-D portrait. Movies of cells seen in rotation brilliantly reveal shape asymmetries, a particularly useful tool for disease diagnosis (see Film 1).

The three cell types examined in the study fell into four distinct nuclear shape categories. Category 1 cell nuclei were slender, with marked concavity. Category 2 cells had a slight concavity and were bulky. Based on these shapes, the first two categories are termed mushroom cap morphology. (The Category 2 mushroom cap morphology was the most common nuclear form seen in all three cell types.) Category 3 nuclei were mostly convex in shape, while Category 4 nuclei were irregular and distorted in shape, (see 3-D renderings in Figure 1).

Importantly, cells drawn from the cancerous cell line showed the largest fraction of irregular, Category 4 and Category 2 nuclei and the smallest fraction of nuclei with a Category 3 convex shape. The malignant cells also displayed the greatest shape heterogeneity within Category 4. The fibrocystic cell sample contained the largest fraction of Category 3 and the lowest fraction of Category 1 nuclei. The largest overall shape heterogeneity with respect to the four shape categories occurred in the normal cells.

Cell and nuclear volume were observed to increase as one moves from

normal to fibrocystic to malignant cells, though fibrocystic cells had, on average, the largest nucleus-to-cytoplasm volume. Textural distinctions among cells and arrangement of chromatin were also observed. In all, the team computed 42 distinct 3-D morphological and textural descriptors of cellular and nuclear structure. Cell-CT technology is able to resolve cell features down to less than a half micron.

Study co-author Roger Johnson, Research Laboratory Manager at the Center for Biosignatures Discovery Automation, stresses that the subtle nuclear differences observed, particularly for the malignant cells, would likely have been missed had the samples been examined with conventional 2-D imagery. As a result, the architecture imaged with Cell-CT supercedes the existing nuclear grades established for cancer diagnosis using a microscope.

Though much progress has been made in understanding the transformation of cells from normal to diseased states, patient outcomes for many forms of cancer remain discouragingly poor. Many believe a new paradigm for investigating such cancers will need to be established, and the field has drawn interested researches from diverse disciplines. Paul Davies, another co-author of the current study is a physicist and cosmologist in ASU's College of Liberal Arts and Sciences and part of a new National Cancer Institute funded consortium, devoted to studying the physical science of cancer: "We expect that insights and methods drawn from physical science will lead to radical new ideas for understanding and tackling cancer," says Davies.

The group's results provide a new window on the variations of nuclear structure that often signal cell malignancy. The unparalleled structural details produced by Cell-CT promise to dramatically improve 3-D nuclear morphometry, leading to a sensitive and specific nuclear grade classification for breast cancer diagnosis.

Medical Xpress

Provided by Arizona State University

Citation: Cell-CT: A new dimension in breast cancer research (2012, January 5) retrieved 25 April 2024 from https://medicalxpress.com/news/2012-01-cell-ct-dimension-breast-cancer.html

This document is subject to copyright. Apart from any fair dealing for the purpose of private study or research, no part may be reproduced without the written permission. The content is provided for information purposes only.