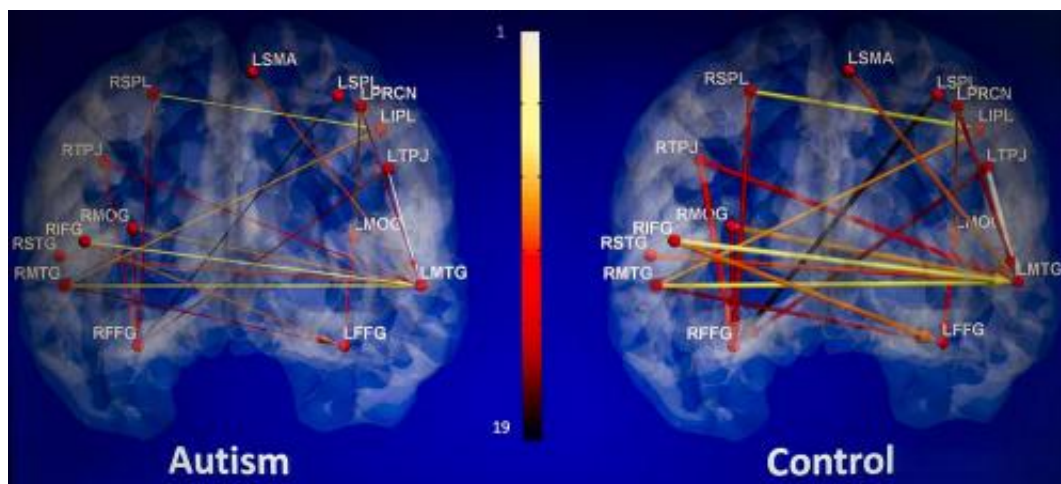


## Research finds brain scans may aid in diagnosis of autism

October 17 2013, by Kelli Hewett Taylor



This brain scan from Kana's study shows weaker neural connectivity in participants with autism compared with participants without autism.

(Medical Xpress)—Joint research from the University of Alabama at Birmingham Department of Psychology and Auburn University indicates that brain scans show signs of autism that could eventually support behavior-based diagnosis of autism and effective early intervention therapies. The findings appear online today in *Frontiers in Human Neuroscience* as part of a special issue on brain connectivity in autism.

"This research suggests [brain connectivity](#) as a neural signature of [autism](#) and may eventually support clinical testing for autism," said Rajesh Kana, Ph.D., associate professor of psychology and the project's senior

researcher. "We found the information transfer between brain areas, causal influence of one brain area on another, to be weaker in autism."

The investigators found that brain connectivity data from 19 paths in [brain scans](#) predicted whether the participants had autism, with an accuracy rate of 95.9 percent.

Kana, working with a team including Gopikrishna Deshpande, Ph.D., from Auburn University's MRI Research Center, studied 15 high-functioning adolescents and adults with autism, as well as 15 typically developing control participants ages 16-34 years. Kana's team collected all data in his autism lab at UAB that was then analyzed using a novel connectivity method at Auburn.

The current study showed that adults with [autism spectrum disorders](#) processed [social cues](#) differently than typical controls. It also revealed the disrupted brain connectivity that explains their difficulty in understanding social processes.

"We can see that there are consistently weaker brain regions due to the disrupted brain connectivity," Kana said. "There's a very clear difference."

Participants in this study were asked to choose the most logical of three possible endings as they watched a series of comic strip vignettes while a functional MRI scanner measured brain activity.

The scenes included a glass about to fall off a table and a man enjoying the music of a street violinist and giving him a cash tip. Most participants in the autism group had difficulty in finding a logical end to the violinist scenario, which required an understanding of emotional and mental states. The current study showed that adults with autism spectrum disorders struggle to process subtle social cues, and altered brain

connectivity may underlie their difficulty in understanding [social processes](#).

"We can see that the weaker connectivity hinders the cross-talk among [brain regions](#) in autism," Kana said.

Kana plans to continue his research on autism.

"Over the next five to 10 years, our research is going in the direction of finding objective ways to supplement the diagnosis of autism with medical testing and testing the effectiveness of intervention in improving brain connectivity," Kana said.

Autism is currently diagnosed through interviews and behavioral observation. Although autism can be diagnosed by 18 months, in reality, earliest diagnoses occur around ages 4-6 as children face challenges in school or social settings.

"Parents usually have a longer road before getting a firm diagnosis for their child now," Kana said. "You lose a lot of intervention time, which is so critical. Brain imaging may not be able to replace the current diagnostic measures; but if it can supplement them at an earlier age, that's going to be really helpful."

The findings of this study build on Kana's research collaborations with Auburn that began in 2010. Lauren Libero, a graduate student in the UAB Department of Psychology, assisted in the research.

Provided by University of Alabama at Birmingham

Citation: Research finds brain scans may aid in diagnosis of autism (2013, October 17) retrieved 19 April 2024 from

<https://medicalxpress.com/news/2013-10-brain-scans-aid-diagnosis-autism.html>

This document is subject to copyright. Apart from any fair dealing for the purpose of private study or research, no part may be reproduced without the written permission. The content is provided for information purposes only.