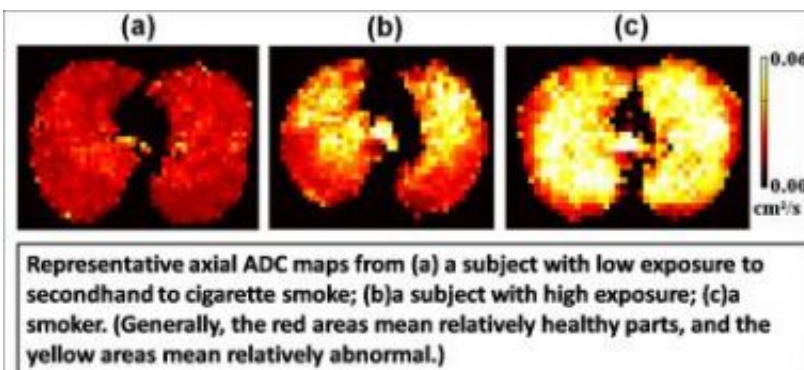


Secondhand smoke damages lungs, MRIs show

November 26 2007



The apparent diffusion coefficient (ADC) measures lung injury, indicated by different colors. Credit: The Children's Hospital of Philadelphia and the University of Virginia

It's not a smoking gun, but it's smoking-related, and it's there in bright medical images: evidence of microscopic structural damage deep in the lungs, caused by secondhand cigarette smoke. For the first time, researchers have identified lung injury to nonsmokers that was long suspected, but not previously detectable with medical imaging tools.

The researchers suggest that their findings may strengthen public health efforts to restrict secondhand smoke.

“We used a special type of magnetic resonance imaging to find these structural changes in the lungs,” said study leader Chengbo Wang, Ph.D.,

a magnetic resonance physicist in the Department of Radiology at The Children's Hospital of Philadelphia. "Almost one-third of nonsmokers who had been exposed to secondhand cigarette smoke for a long time developed these structural changes." Formerly at the University of Virginia, Wang collaborated with radiology researchers at that institution, where they acquired the MRIs from adult smokers and nonsmokers.

Wang presented the team's findings in Chicago at the annual meeting of the Radiological Society of North America. Although the participants in the research study were adults, Wang said the results have implications for the 35 percent of American children who live in homes where regular smoking occurs.

The researchers studied 60 adults between ages 41 and 79, 45 of whom had never smoked. The 45 non-smokers were divided into groups with low and high exposure to secondhand smoke; the high-exposure subjects had lived with a smoker for at least 10 years, often during childhood. The 15 current or former smokers formed a positive control group.

The research team prepared an isotope of helium called helium-3 by polarizing it to make it more visible in the MRI. Researchers diluted the helium in nitrogen and had research subjects inhale the mixture. Unlike ordinary MRIs, this MRI machine measured diffusion, the movement of helium atoms, over 1.5 seconds. The helium atoms moved a greater distance than in the lungs of normal subjects, indicating the presence of holes and expanded spaces within the alveoli, tiny sacs within the lungs.

The researchers found that almost one-third of the non-smokers with high exposure to secondhand smoke had structural changes in their lungs similar to those found in the smokers. "We interpreted those changes as early signs of lung damage, representing very mild forms of emphysema," said Wang. Emphysema, a lung disease that is a major

cause of death in the U.S., is commonly found in heavy smokers.

The researchers also found a seemingly paradoxical result among two-thirds of the high-exposure group of non-smokers—diffusion measurements that were lower than those found in the low-exposure group. Although these findings require more study, said Wang, they may reflect a narrowing in airways caused by early stages of another lung disease, chronic bronchitis.

“To our knowledge, this is the first imaging study to find lung damage in non-smokers heavily exposed to secondhand smoke,” said Wang. “We hope our work strengthens the efforts of legislators and policymakers to limit public exposure to secondhand smoke.”

Source: Children's Hospital of Philadelphia

Citation: Secondhand smoke damages lungs, MRIs show (2007, November 26) retrieved 27 April 2024 from <https://medicalxpress.com/news/2007-11-secondhand-lungs-mris.html>

<p>This document is subject to copyright. Apart from any fair dealing for the purpose of private study or research, no part may be reproduced without the written permission. The content is provided for information purposes only.</p>
--