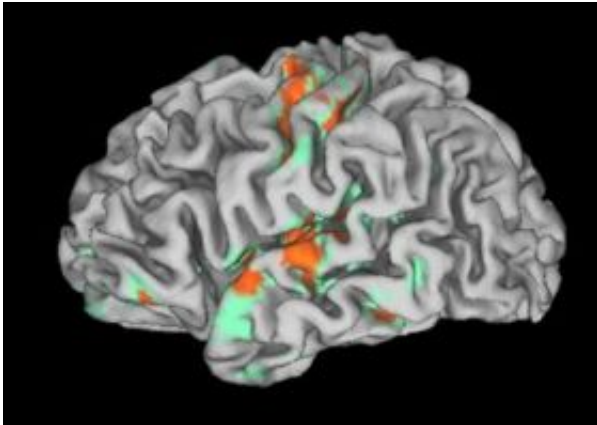


A new hand -- and signs of sensory recovery

October 9 2008



Activation of the left cerebral hemisphere during sensory stimulation of the transplanted right palm as viewed by enhancement of fMRI findings. Credit: Courtesy of Scott Frey

Four months after a successful hand transplant -- 35 years after amputation in an industrial accident at age 19 -- a 54-year-old man's emerging sense of touch is registered in the former "hand area" of the his brain, says a University of Oregon neuroscientist.

The finding, appearing online in advance of regular publication in the Oct. 14 issue of the journal *Current Biology*, centers only on the man's right palm of a donated hand, which was attached along with major nerves, bones, tendons, and muscle, in a surgery by Kleinert, Kutz and Associates Hand Care Center of Louisville, Ken. A co-author, Dr. Warren C. Breidenbach, also was the lead surgeon of the team that

performed the first long-term successful hand transplant in 1999.

Still to be determined, said lead author Scott H. Frey, UO psychology professor and director of the Robert and Beverly Lewis Center for NeuroImaging, is how the brain's map of the individual fingers will evolve with increasing sensation. Just four months post-surgery, initial touch sensations were reported on the thenar eminence -- muscle on the palm just below the thumb -- and on the lateral base of the thumb near the radial nerve.

Functional magnetic resonance imaging was used to record brain activity while sensory stimuli were delivered to the hands and faces of the transplant recipient and four control participants. Results showed that sensory signals from the transplanted hand are being processed in the same brain regions that would have formerly handled sensations from the hand prior to amputation.

"This individual is very unique from a brain standpoint," Frey said. "We know that when someone loses a hand, there are reorganizational changes that take place in areas of the brain that have received sensory input from that hand. Yet, even after 35 years, the restoration of sensory input seems capable of recapturing the former territory of the hand. The capacity of the brain to reverse these changes is all the more striking in light of the fact that his brain was fully mature when the amputation occurred. We believe that this work may have far reaching implications for our understanding of brain plasticity in adulthood and neurorehabilitation."

The patient received the transplant in December 2006. After losing his hand in a machine press accident, he wore a standard cable-hook-prosthetic device, allowing him to continue working.

Reorganization in sensory regions begins within hours of a limb loss.

Research on animals has shown that neurons that had been devoted to receiving sensory inputs from the limb take on new duties. Exactly what happens is not entirely clear, nor are we certain how long such changes continue Frey said, "but one way to think about it is that none of the brain's real estate is left vacant for very long." Over time, the injured man reported gradual reductions of phantom sensations and pain often reported by amputees.

Recovery of sensation and the brain's systematic mapping of the hand-to-brain network, in this case, involve only gross hand map zones, referring to activity of major nerves that were reattached, not any peripheral connections to individual digits. "We don't know what that map will look like in the future as the nerves of his fingers regenerate and sensation improves," Frey said.

Physicians at the Hand Care Center have performed four of the almost 30 hand transplants done worldwide. Advances in imaging technology are allowing neuroscientists to map the brain before and after surgeries, opening new insights into brain reorganization and recovery, Frey said.

"What this hand transplant allows us to ask for the very first time in history is: Following reorganizational changes, is it possible to reverse the restoration of sensory input into the brain? The answer, which appears to be yes, extends well beyond the case of hand transplants," he said. "In general, it gives us some ideas about the reorganizational potential of the brain."

Source: University of Oregon

Citation: A new hand -- and signs of sensory recovery (2008, October 9) retrieved 23 April 2024 from <https://medicalxpress.com/news/2008-10-sensory-recovery.html>

This document is subject to copyright. Apart from any fair dealing for the purpose of private study or research, no part may be reproduced without the written permission. The content is provided for information purposes only.