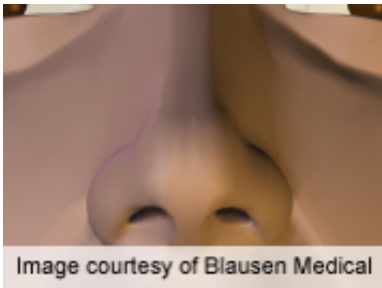


# Objective, subjective post-rhinoplasty breathing evaluated

September 14 2012

---



Septorhinoplasty is associated with subjective improvement in nasal patency as well as increases in nasal volume and decreases in nasal resistance, particularly in those with severe obstruction before surgery, according to a study published online Sept. 10 in the *Archives of Facial Plastic Surgery*.

(HealthDay)—Septorhinoplasty is associated with subjective improvement in nasal patency as well as increases in nasal volume and decreases in nasal resistance, particularly in those with severe obstruction before surgery, according to a study published online Sept. 10 in the *Archives of Facial Plastic Surgery*.

To examine subjective and objective nasal patency after rhinoplasty, Richard A. Zoumalan, M.D., of Cedars Sinai Medical Center in Beverly Hills, Calif., and Minas Constantinides, M.D., of the New York University School of Medicine in New York City, conducted a [retrospective study](#) involving 31 [patients](#) who underwent septorhinoplasty with potassium titanyl phosphate laser turbinate

reduction for cosmetic and functional reasons.

The researchers identified a significant mean subjective improvement in breathing scores, which was 38 percent overall. Although the overall mean volume increased and overall resistance decreased, these changes were only significant for the right side. Results were similar in patients stratified according to treatment with other procedures, including spreader [grafts](#) and alar batten grafts, and did not differ in the absence of osteotomies. Patients with severe obstruction achieved the greatest improvement in all measured values, including in minimal cross-sectional area (MCA), which improved significantly, by an average of 55 percent. The MCA did not change but, on the left side, the distance of the MCA of the [nasal cavity](#) moved 0.23 cm anteriorly. This anterior shift was the only significant change for patients with normal preoperative MCA values.

"Septorhinoplasty increases nasal volume and decreases nasal resistance. In addition, it advances the MCA anteriorly," the authors write. "These changes coexist with subjective improvements in nasal patency, which suggests that this new anatomic configuration after septorhinoplasty and inferior turbinoplasty creates a positive outcome on nasal airflow."

**More information:** [Abstract](#)  
[Full Text \(subscription or payment may be required\)](#)

Copyright © 2012 [HealthDay](#). All rights reserved.

Citation: Objective, subjective post-rhinoplasty breathing evaluated (2012, September 14)  
retrieved 5 May 2024 from  
<https://medicalxpress.com/news/2012-09-subjective-post-rhinoplasty.html>

This document is subject to copyright. Apart from any fair dealing for the purpose of private
---

study or research, no part may be reproduced without the written permission. The content is provided for information purposes only.