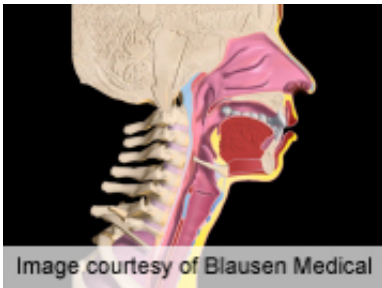


# Dysphagia not tied to post-anterior cervical op swelling

October 7 2012

---



Although significant soft-tissue swelling can occur after anterior cervical discectomy and fusion procedures, the width of the prevertebral soft-tissue swelling on radiographic analysis does not correlate with the severity of postoperative dysphagia, according to research published in the August issue of *The Spine Journal*.

(HealthDay)—Although significant soft-tissue swelling can occur after anterior cervical discectomy and fusion (ACDF) procedures, the width of the prevertebral soft-tissue swelling on radiographic analysis does not correlate with the severity of postoperative dysphagia, according to research published in the August issue of *The Spine Journal*.

To examine whether anterior soft-tissue swelling is greater in patients with postoperative [dysphagia](#), Christopher K. [Kepler](#), M.D., M.B.A., of the Rothman Institute/[Thomas Jefferson](#) University in Philadelphia, and colleagues conducted a prospective, cohort study involving 43 patients who had undergone one- or two-level ACDF using allograft bone and

anterior instrumentation. Dysphagia was assessed before and after surgery using a questionnaire which included a dysphagia numeric rating scale (DNRS).

The researchers found a significant increase in the anterior soft-tissue shadow width at all levels, with the exception of C1 at two weeks and C1 and C2 at six weeks. Two weeks after surgery, 18 patients had no symptoms or only mild dysphagia (average DNRS, 1.1) and 25 patients experienced moderate-to-severe dysphagia (average DNRS, 5.3). Compared with those with little or no dysphagia, patients with more severe dysphagia did not display any significant differences in soft-tissue measurements at any level, on radiographic analysis. No correlation was found at any time point between the DNRS and the width of anterior soft-tissue swelling.

"Despite the common perception that soft-tissue swelling plays a prominent role in the [pathogenesis](#) of dysphagia after ACDF, we found no objective evidence of greater soft-tissue shadow width in patients with moderate or significant postoperative dysphagia in comparison to patients without symptoms or with only mild complaints of difficulty swallowing," the authors write.

Several authors disclosed [financial ties](#) to the medical device industry.

**More information:** [Abstract](#)  
[Full Text \(subscription or payment may be required\)](#)

Copyright © 2012 [HealthDay](#). All rights reserved.

Citation: Dysphagia not tied to post-anterior cervical op swelling (2012, October 7) retrieved 24 April 2024 from <https://medicalxpress.com/news/2012-10-dysphagia-tied-post-anterior-cervical-op.html>

This document is subject to copyright. Apart from any fair dealing for the purpose of private study or research, no part may be reproduced without the written permission. The content is provided for information purposes only.