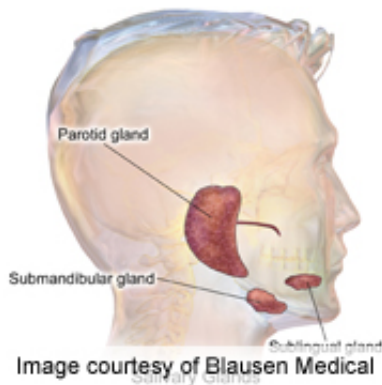


# Salivary gland ultrasonography improves Sjogren's diagnosis

November 3 2012

---



The addition of salivary-gland ultrasonography to American-European Consensus Group classification criteria improves the accuracy of diagnosis of primary Sjögren's syndrome, according to a study published online Oct. 25 in *Arthritis & Rheumatism*.

(HealthDay)—The addition of salivary-gland ultrasonography (SGUS) to American-European Consensus Group (AECG) classification criteria improves the accuracy of diagnosis of primary Sjögren's syndrome (pSS), according to a study published online Oct. 25 in *Arthritis & Rheumatism*.

Divi Cornec, M.D., from the Brest Teaching Hospital in France, and colleagues graded the echostructure of bilateral parotid and submandibular glands in a prospective cohort of 158 patients with suspected pSS. Gland size was measured and parotid blood flow was

analyzed using Doppler waveforms.

The researchers found that 78 patients were diagnosed by the experts as having pSS, 78.2 percent of whom met AECG criteria. Poor diagnostic performance was seen with Doppler analysis and gland size measurement. The best performance for echostructure grades was for the highest grade of one of the four glands in each patient, with the optimal grade cut-off of  $\geq 2/4$ , which had 62.8 percent sensitivity and 95.0 percent specificity. Using the five variables selected by logistic regression analysis—(salivary flow\*1.5) + Schirmer\*1.5 + ([salivary gland](#) biopsy\*3) + (SSA/SSB\*4.5) + SGUS\*2—a weighted score was constructed. A score  $\geq 5/12.5$  had 85.7 percent sensitivity and 94.9 percent specificity on receiver operator characteristic curve analysis, compared with 77.9 and 98.7 percent for AECG criteria. The addition of SGUS to AECG criteria increased sensitivity to 87.0 percent, while specificity remained similar.

"Given the new hope generated by the introduction of biotherapeutic agents for the treatment of pSS, the AECG criteria should be revised to take into account changes in medical knowledge and imaging technologies," the authors write. "Further research and external validation of ultrasonography is needed in a larger cohort of patients with suspected pSS."

**More information:** [Abstract](#)  
[Full Text \(subscription or payment may be required\)](#)

Copyright © 2012 [HealthDay](#). All rights reserved.

Citation: Salivary gland ultrasonography improves Sjogren's diagnosis (2012, November 3)  
retrieved 28 April 2024 from  
<https://medicalxpress.com/news/2012-11-salivary-gland-ultrasonography-sjogren-diagnosis.html>

This document is subject to copyright. Apart from any fair dealing for the purpose of private study or research, no part may be reproduced without the written permission. The content is provided for information purposes only.