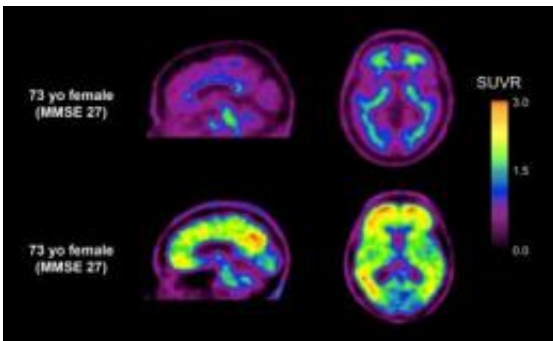


# Tracing the impact of amyloid beta in mild cognitive impairment

January 15 2013



It should just say that in two women of the same age with similar memory complaints, one (top images) has no evidence of amyloid plaques while the other (bottom row) has extensive amyloid plaques (red and yellow areas) in the cortex around the edge of the brain indicating the presence of Alzheimer's disease. Credit: Christopher Rowe and Victor Villemagne

The amount of amyloid  $\beta$  ( $A\beta$ ) in the brains of people with mild cognitive impairment (MCI) is contributing to early memory loss, and increases with severity of symptoms, finds a study in BioMed Central's open access journal *Alzheimer's Research & Therapy*. The non-invasive study which used  $^{18}F$ -florbetaben to find  $A\beta$  plaques in brain scans to also show that in MCI the affect of  $A\beta$  on memory loss is independent of other aspects of mental decline.

Positron emission tomography (PET) has previously relied on carbon-11 labeling of  $A\beta$ , however this study uses  $^{18}F$ -florbetaben which can be

used for longer and allow more patients to be scanned at lower cost. A higher than normal amount of A $\beta$  was found in half of the PET scans of people with MCI. Interestingly there was a strong association between A $\beta$  and [memory loss](#), but not with other features of neurodegeneration, such as hippocampal atrophy or the white matter hyperintensities frequently seen on MRI later in the development of Alzheimer's disease.

Prof Christopher Rowe, from Austin Health, Australia and the University of Melbourne, who led the study explained why it is important, "MCI is thought to affect between one in five and one in ten of all adults over the age of 65, and, although some of these will go on to develop dementia within a few years, the majority can lead a relatively normal life. Detection of A $\beta$  plaques in MCI indicates early Alzheimer's disease, while a negative scan eliminates this possibility. Consequently a negative scan is very reassuring while a positive scan can lead to earlier and more appropriate medical and social management."

**More information:** 18F-florbetaben Abeta imaging in mild cognitive impairment Kevin Ong, Victor L Villemagne, Alex Bahar-Fuchs, Fiona Lamb, Gaël Chételat, Parnesh Raniga, Rachel S Mulligan, Olivier Salvado, Barbara Putz, Katrin Roth, Colin L Masters, Cornelia B Reininger and Christopher C Rowe, *Alzheimer's Research & Therapy* (in press)

Provided by BioMed Central

Citation: Tracing the impact of amyloid beta in mild cognitive impairment (2013, January 15) retrieved 29 April 2024 from <https://medicalxpress.com/news/2013-01-impact-amyloid-beta-mild-cognitive.html>

This document is subject to copyright. Apart from any fair dealing for the purpose of private

study or research, no part may be reproduced without the written permission. The content is provided for information purposes only.