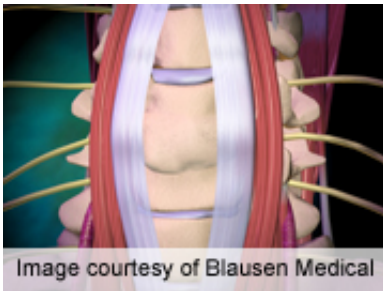


Pre-op MRI predicts outcome of cervical spondylotic myelopathy

June 19 2013



For patients with cervical spondylotic myelopathy, preoperative magnetic resonance imaging signal changes are predictive of baseline neurologic status and postoperative recovery, according to a study published in the June 15 issue of *Spine*.

(HealthDay)—For patients with cervical spondylotic myelopathy (CSM), preoperative magnetic resonance imaging (MRI) signal changes are predictive of baseline neurologic status and postoperative recovery, according to a study published in the June 15 issue of *Spine*.

Babak Arvin, M.D., from Queens Hospital in Romford, U.K., and colleagues conducted a blinded observational study to examine whether quantitative assessment of preoperative MRI can predict baseline patient status and postoperative neurological recovery in a cohort of 57 patients with CSM.

The researchers found that preoperative change in low T1 signal

correlated with significantly lower modified Japanese Orthopaedic Association (mJOA) scores, higher Nurick Grade, decreased grip, impaired 30-meter walk cadence (Wc) and time (Wt), and poor Berg Balance Scale scores at baseline. Compared with diffuse or no T2 signal, focal high T2 signal correlated with lower mJOA scores and higher Nurick Grade. There was a significant increase in Wt, Wc, and Berg Balance Scale with preoperative segmentation of T2 signal. Lower postoperative grip and greater Wt and Wc correlated with preoperative T1 signal. There was a significant correlation between preoperative focal T2 signal with poorer postoperative Wt, Wc, and Nurick Grade. A negative correlation was seen between preoperative maximal cord compromise and postoperative Short Form-36 mental scores.

"[MRI signal](#) changes are predictive of baseline neurological status and postoperative recovery," the authors write. "MRI indicators of poorer outcome include the presence of low T1 signal, focal increased T2 signal, and segmentation of T2 signal changes."

More information: [Abstract](#)
[Full Text \(subscription or payment may be required\)](#)

[Health News](#) Copyright © 2013 [HealthDay](#). All rights reserved.

Citation: Pre-op MRI predicts outcome of cervical spondylotic myelopathy (2013, June 19)
retrieved 4 May 2024 from
<https://medicalxpress.com/news/2013-06-pre-op-mri-outcome-cervical-spondylotic.html>

This document is subject to copyright. Apart from any fair dealing for the purpose of private study or research, no part may be reproduced without the written permission. The content is provided for information purposes only.
