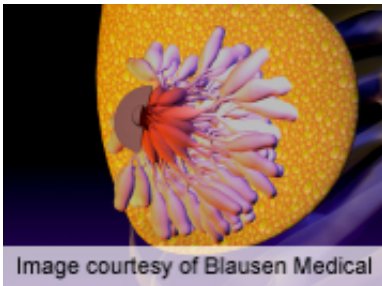


Multiple bilateral circumscribed breast masses usually benign

September 17 2013



Multiple bilateral circumscribed breast masses detected with ultrasound screening are almost always benign, according to research published in the September issue of *Radiology*.

(HealthDay)—Multiple bilateral (MB) circumscribed breast masses detected with ultrasound screening are almost always benign, according to research published in the September issue of *Radiology*.

Wendie A. Berg, M.D., Ph.D., from the American College of Radiology Imaging Network in Philadelphia, and colleagues analyzed data from 2,662 participants and 7,473 screening studies at 21 international sites. Ultrasound studies were interpreted with blinding to mammography results. Simple [cysts](#) were noted, and features of all other Breast Imaging Reporting and Data System findings were recorded. Biopsy or mammography and ultrasound were used to determine malignancy rates at a minimum of 11 months of follow-up.

The researchers found that, based on the 2,172 participants (from 6,103 screening studies; median age at baseline, 54 years) ultimately included, there were 1,454 unique findings using ultrasound. There were 135 participants (6.2 percent) with 153 unique MB circumscribed breast masses, with no malignancies. In the 1,319 participants with 2,464 non-MB [lesions](#) (60.7 percent), there were 1,038 solitary circumscribed masses with a malignancy rate of 0.8 percent. For the 836 solitary circumscribed masses with at least two years of follow-up, the [malignancy](#) rate was 0.4 percent. More than 60 percent of the 135 women with MB circumscribed masses also had a solitary lesion, with two of these 82 women having cancer.

"We recommend diagnostic follow-up at one year for MB circumscribed benign-appearing masses identified at screening ultrasound, with resumption of screening thereafter if the mass is stable, but we recognize that larger studies need to be performed to document that this is a valid approach," the authors write.

Several authors disclosed financial ties to the imaging industry.

More information: [Abstract](#)
[Full Text \(subscription or payment may be required\)](#)

Copyright © 2013 [HealthDay](#). All rights reserved.

Citation: Multiple bilateral circumscribed breast masses usually benign (2013, September 17)
retrieved 19 April 2024 from
<https://medicalxpress.com/news/2013-09-multiple-bilateral-circumscribed-breast-masses.html>

<p>This document is subject to copyright. Apart from any fair dealing for the purpose of private study or research, no part may be reproduced without the written permission. The content is provided for information purposes only.</p>
--