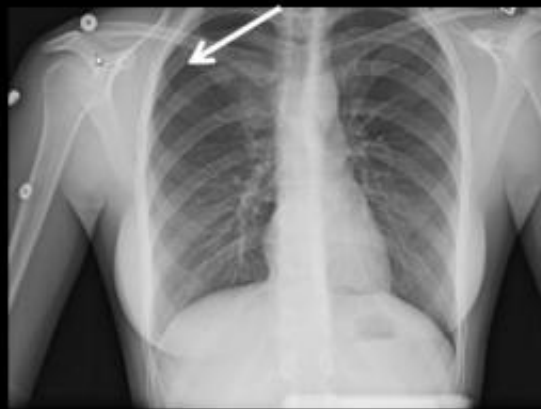

Many chest X-rays in children are unnecessary

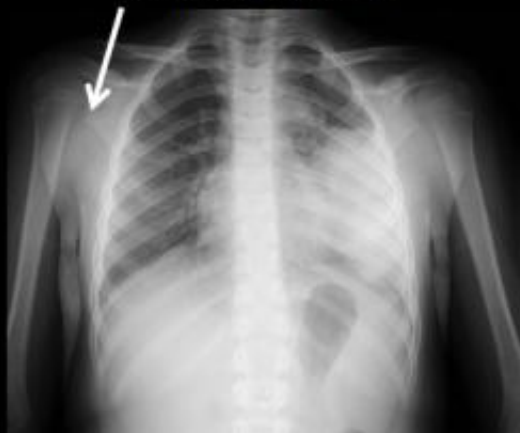December 3 2014

Examples of positive chest radiographs for the indication of chest pain accounting for approximately 12% of the total exams performed

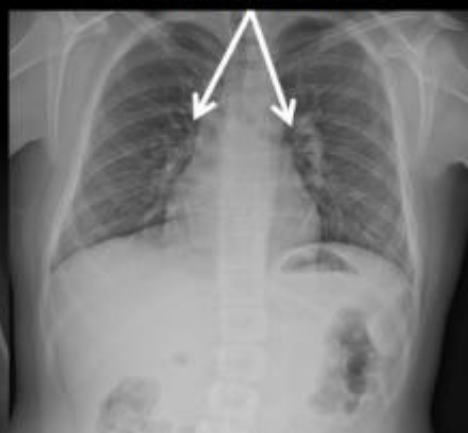Pneumothorax



Round Pneumonia



Perihilar Inflammation



Examples of positive chest x-rays. Credit: RSNA

Researchers at Mayo Clinic found that some children are receiving chest X-rays that may be unnecessary and offer no clinical benefit to the patient, according to a study presented today at the annual meeting of the Radiological Society of North America (RSNA).

"Chest X-rays can be a valuable exam when ordered for the correct indications," said Ann Packard, M.D., radiologist at the Mayo Clinic in Rochester, Minn. "However, there are several indications where pediatric [chest](#) X-rays offer no benefit and likely should not be performed to decrease radiation dose and cost."

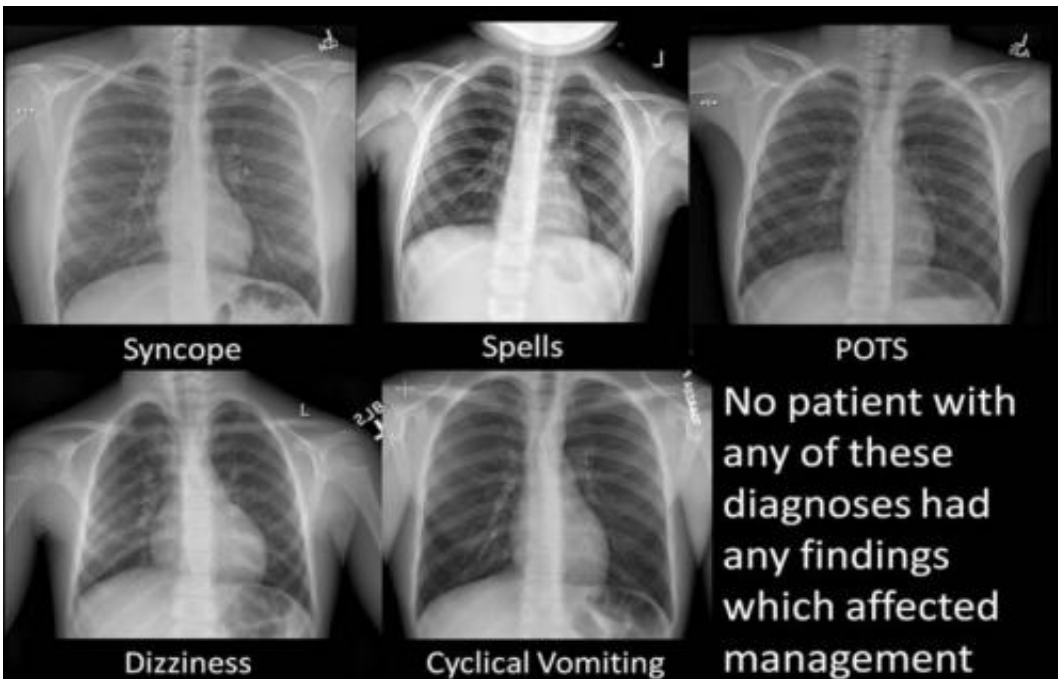
Dr. Packard and co-author, Kristen B. Thomas, M.D., head of the pediatric division at Mayo Clinic and assistant professor of radiology at Mayo Medical School, reviewed data from 719 pediatric chest X-ray exams ordered between 2008 and 2014 in Mayo Clinic's inpatient, outpatient and emergency room settings. The patients undergoing the exams ranged in age from newborn to 17 years old.

Of the 719 X-ray exams, 377 exams were ordered for [chest pain](#), 98 indicated syncope (fainting) or presyncope, 21 indicated spells (a general feeling of being unwell or under distress), 37 indicated postural orthostatic hypotension (POTS)—a condition in which blood pressure drops suddenly when the individual stands up from sitting or lying down, 185 indicated dizziness, and one exam indicated cyclical vomiting. Eighty-two of the 719 exams were excluded due to congenital or other known heart disease, and other causes.

The researchers found that in approximately 88 percent of the remaining 637 patients, the exam did not alter clinical treatment.

None of the patients who underwent X-rays for indications including syncope, spells, POTS, dizziness or cyclical vomiting had any finding that affected treatment. Thirty-nine of the 330 non-excluded X-rays for

chest pain were positive for pneumonia, bronchial inflammation, trauma, or other conditions.



Examples of negative x-rays which had no affect on treatment. Credit: RSNA

"Approximately 12 percent of the chest X-rays for chest pain were positive and included respiratory symptoms such as cough, fever or trauma," Dr. Packard said. "There were no positive findings in any chest X-ray for syncope, dizziness, spells, cyclical vomiting or POTS for the past five years, even in our tertiary care center with referrals for rare diseases or unusual presentations."

Optimizing radiation exposure and cost effectiveness are important topics in today's healthcare environment, particularly in a pediatric population, Dr. Packard noted.

"This study addresses both of these issues, which is important not only for physicians but also for young patients and their parents," she said. "I would like this research to help guide clinicians and deter them from ordering unnecessary exams which offer no [clinical benefit](#) to the patient."

Provided by Radiological Society of North America

Citation: Many chest X-rays in children are unnecessary (2014, December 3) retrieved 23 April 2024 from <https://medicalxpress.com/news/2014-12-chest-x-rays-children-unnecessary.html>

This document is subject to copyright. Apart from any fair dealing for the purpose of private study or research, no part may be reproduced without the written permission. The content is provided for information purposes only.