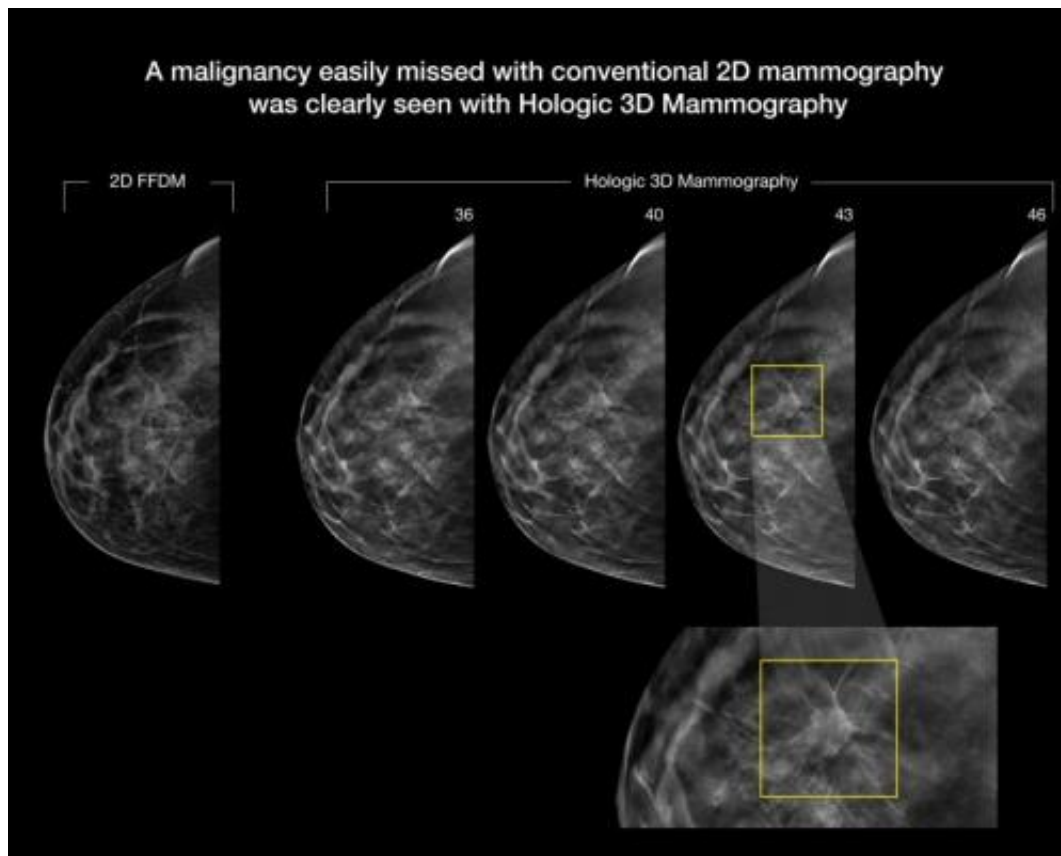


3-D mammography improves cancer detection in dense breasts

December 2 2014



A malignancy easily missed on 2-D mammography was clearly seen on 3-D mammography. Credit: RSNA

A major new study being presented at the annual meeting of the Radiological Society of North America (RSNA) has found that digital breast tomosynthesis, also known as 3-D mammography, has the

potential to significantly increase the cancer detection rate in mammography screening of women with dense breasts.

Breasts are considered dense if they have a lot of fibrous or glandular tissue but not much fatty tissue. Research has shown that dense breasts are more likely to develop cancer, a problem compounded by the fact that cancer in dense breasts can be difficult to detect on mammograms.

Other imaging modalities like ultrasound and MRI are often used to help find cancers that can't be seen on mammograms, but both modalities have higher rates of false-positive findings, which are suspicious findings that turn out not to be cancer. This higher false-positive rate often results in more tests and unnecessary biopsies, making MRI and ultrasound expensive to implement in high-volume [screening](#) programs, according to study lead author Per Skaane, M.D., Ph.D., from the Department of Radiology at Oslo University Hospital in Oslo, Norway.

Dr. Skaane and colleagues have been studying tomosynthesis as a promising [breast cancer screening](#) option that addresses some of the limitations of [mammography](#) by providing 3-D views of the breast.

"Tomosynthesis could be regarded as an improvement of mammography and would be much easier than MRI or ultrasound to implement in organized screening programs," Dr. Skaane said. "So the intention of our study was to see if tomosynthesis really would significantly increase the cancer detection rate in a population-based [mammography screening](#) program."

The researchers compared cancer detection using full-field digital mammography (FFDM) versus FFDM plus digital breast tomosynthesis in 25,547 women between the ages of 50 and 69. Breast density was classified based on the American College of Radiology's Breast Imaging-Reporting and Data System (BI-RADS). The BI-RADS breast density

scale runs from 1 to 4, with 1 being the least dense and 4 being the most dense.

There were 257 malignancies detected on FFDM and a combination of FFDM and tomosynthesis in the study group, including 105 in the density 2 group and 110 in density 3. Of the 257 cancers, 211, or 82 percent were detected with FFDM plus tomosynthesis, a significant improvement over the 163, or 63 percent, detected with FFDM alone.

FFDM plus tomosynthesis pinpointed 80 percent of the 132 cancer cases in women with dense breasts, compared to only 59 percent for FFDM alone.

"Our findings are extremely promising, showing an overall relative increase in the cancer detection rate of about 30 percent," Dr. Skaane said. "Stratifying the results on invasive cancers only, the relative increase in cancer detection was about 40 percent."

Tomosynthesis not only improved the cancer detection rate in women with [dense breasts](#), it also helped increase detection for women in the "fatty breast" BI-RADS categories. The addition of tomosynthesis to FFDM improved the [cancer detection](#) rate from 68 percent to 84 percent in [women](#) with BI-RADS density 1 or 2 breasts.

"Our results show that implementation of tomosynthesis might indicate a new era in breast cancer screening," Dr. Skaane said.

Provided by Radiological Society of North America

Citation: 3-D mammography improves cancer detection in dense breasts (2014, December 2) retrieved 4 May 2024 from <https://medicalxpress.com/news/2014-12-d-mammography-cancer-dense-breasts.html>

This document is subject to copyright. Apart from any fair dealing for the purpose of private study or research, no part may be reproduced without the written permission. The content is provided for information purposes only.