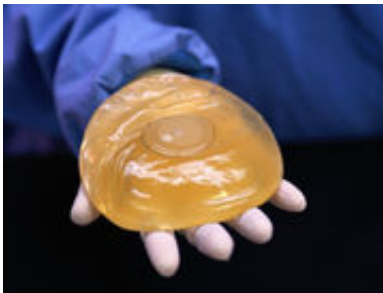


Internal mammary lymph nodes ID'd on MRI likely to be benign

October 28 2015



(HealthDay)—Among women with breast cancer and silicone implant reconstruction, internal mammary lymph nodes (IMLNs) identified at implant-protocol breast magnetic resonance imaging (MRI) are more likely to be benign than malignant, according to a study published in the November issue of *Radiology*.

Elizabeth J. Sutton, M.D., from the Memorial Sloan-Kettering Cancer Center in New York City, and colleagues examined the incidence of benign and malignant IMLNs at MRI among 923 [women](#) with a history of treated breast cancer and silicone implant reconstruction. Participants underwent postoperative implant-protocol MRI with or without position emission tomography (PET)/computed tomography (CT).

The researchers found that the median time from reconstructive surgery

to the first MRI was 49 months. Overall, 37.6 percent of the women had IMLNs at MRI. The median short-axis measurement was 0.40 cm, while the median long-axis measurement was 0.70 cm. Adequate follow-up was reported for 22.4 percent of the patients; only one of the 207 IMLNs was malignant, with a positive predictive value (PPV) of 0.005. A total of 6.3 percent of participants (58 patients) underwent PET/CT; 67.2 percent of these had IMLN at MRI. Of the 58 [patients](#) with adequate follow-up, 20.7 percent had fluorine 18 fluorodeoxyglucose-avid IMLN, with a median standardized uptake value of 2.30; only one of these was malignant (PPV, 0.083).

"IMLNs identified at implant-protocol breast MRI after oncoplastic surgery for [breast cancer](#) are overwhelmingly more likely to be benign than malignant," the authors write.

One author disclosed financial ties to BioClinica.

More information: [Full Text \(subscription or payment may be required\)](#)

Copyright © 2015 [HealthDay](#). All rights reserved.

Citation: Internal mammary lymph nodes ID'd on MRI likely to be benign (2015, October 28) retrieved 3 May 2024 from <https://medicalxpress.com/news/2015-10-internal-mammary-lymph-nodes-idd.html>

<p>This document is subject to copyright. Apart from any fair dealing for the purpose of private study or research, no part may be reproduced without the written permission. The content is provided for information purposes only.</p>
--