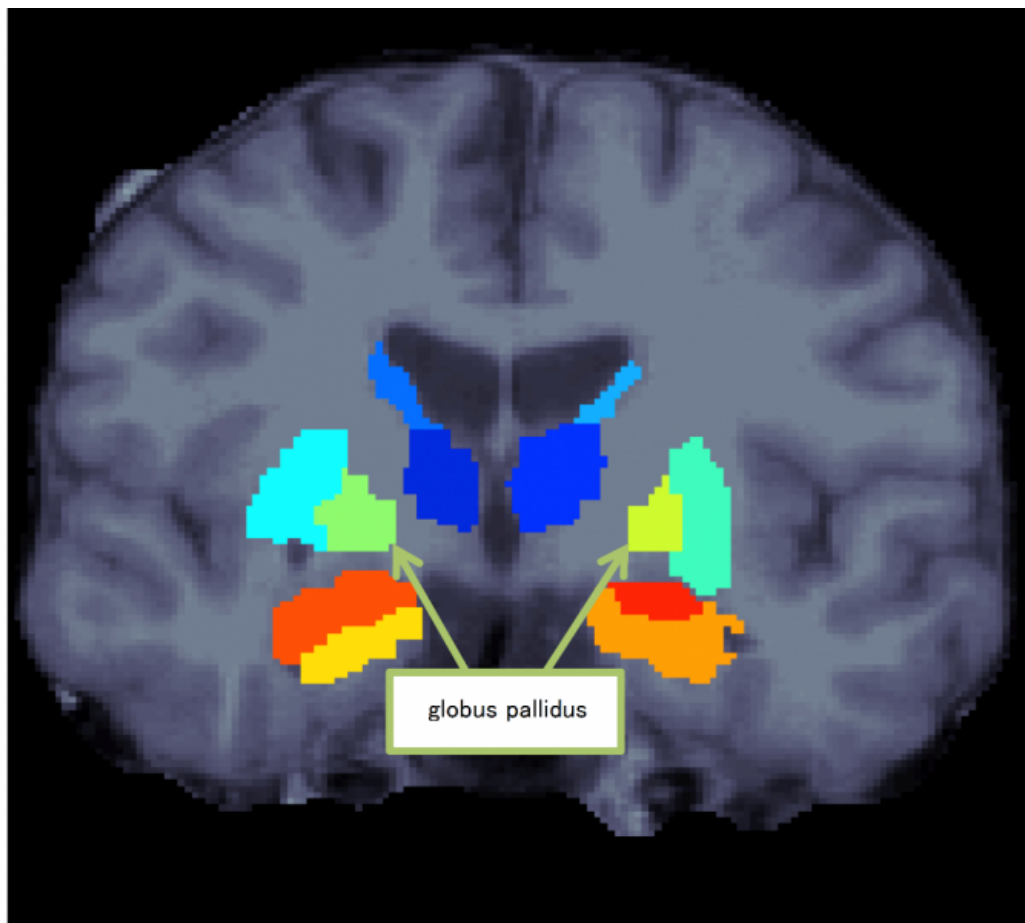


# Discovery of the characteristics of subcortical regions in schizophrenia

March 18 2016

---



Subcortical structures

A Japanese research group found that patients with schizophrenia

demonstrated a specific leftward volumetric asymmetry for the globus pallidus, one of the basal ganglia of the brain. The basal ganglia are involved in motivation and volition, the impairment of which may result in difficulties in social life. This finding is expected to help elucidate the underlying pathological mechanisms of schizophrenia. Moreover, it will be a step toward the development of therapeutic strategies for schizophrenia.

A research group led by Ryota Hashimoto, an associate professor at Osaka University, Naohiro Okada, a graduate student at the University of Tokyo, and Kiyoto Kasai, a professor at the University of Tokyo, replicated prior findings that the volume of globus pallidus (one of the [basal ganglia](#) in the brain) in [schizophrenia](#) was larger than that in healthy subjects. Also, the group found that patients with schizophrenia demonstrated a specific leftward volumetric asymmetry for the globus pallidus.

They compared and analyzed [magnetic resonance imaging](#) (MRI) brain images of 1,680 healthy individuals and 884 patients with schizophrenia from 11 research institutes participating in Cognitive Genetics Collaborative Research Organization (COCORO), and examined the differences between schizophrenia and healthy controls in the subcortical regional volumes and their asymmetries.

Compared to controls, patients with schizophrenia demonstrated smaller bilateral hippocampus, amygdala, thalamus and accumbens volumes as well as intracranial volume, but larger bilateral caudate, putamen, pallidum and lateral ventricle volumes. Also, [patients](#) with schizophrenia demonstrated a specific leftward asymmetry for globus pallidus volume.

These results suggest the possibility of aberrant laterality in neural pathways and connectivity patterns related to the globus pallidus in schizophrenia. Further, through the elucidation of the underlying

pathological mechanisms, it will be a step toward the development of [therapeutic strategies](#) for schizophrenia.

**More information:** N Okada et al. Abnormal asymmetries in subcortical brain volume in schizophrenia, *Molecular Psychiatry* (2016). DOI: [10.1038/mp.2015.209](https://doi.org/10.1038/mp.2015.209)

Provided by Osaka University

Citation: Discovery of the characteristics of subcortical regions in schizophrenia (2016, March 18) retrieved 6 May 2024 from <https://medicalxpress.com/news/2016-03-discovery-characteristics-subcortical-regions-schizophrenia.html>

This document is subject to copyright. Apart from any fair dealing for the purpose of private study or research, no part may be reproduced without the written permission. The content is provided for information purposes only.