Medical Xpress

Venlafaxine-induced rise in intraocular pressure described

May 9 2016

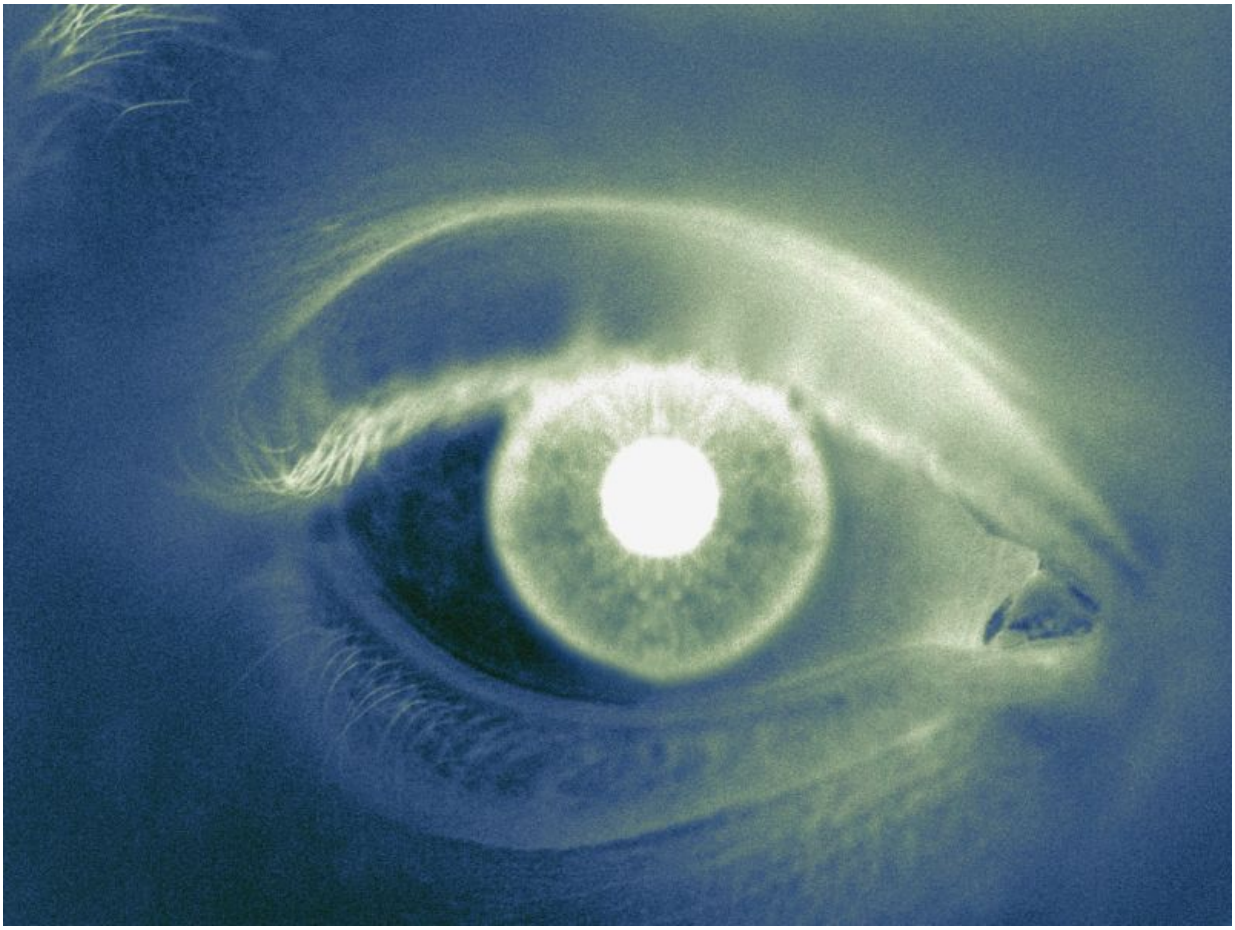

(HealthDay)—In a case report published online April 30 in *Clinical &*

Experimental Ophthalmology, venlafaxine-induced increase in intraocular pressure (IOP) is described in a patient with open angle glaucoma.

Verona E. Botha, M.B., Ch.B., from Waikato District Health Board in Hamilton, New Zealand, and colleagues describe a 65-year-old Caucasian male with chronic open angle glaucoma who started venlafaxine 225 mg once daily for a major depressive episode. After reporting frontal headaches shortly after treatment initiation, the initial dose was reduced to 75 mg, with complete symptom resolution.

The authors note that three months after venlafaxine initiation, at routine glaucoma follow-up, the patient's IOP had increased to 50 mm Hg in the right (OD) and 30 mm Hg in the left (OS) from a previous level of 14 mm Hg bilaterally. He was asymptomatic; no change was seen in angle morphology or indication of intraocular inflammation. Venlafaxine was discontinued immediately and topical brimonidine was commenced to both eyes; IOP improved to 13 and 11 mm Hg OD and OS, respectively. The transient IOP elevation resulted in permanent retinal nerve fiber damage, with increased optic disc cupping and visual field progression in the right eye. The patient received dothiepin, with no impact on IOP over two years.

"Awareness that IOP may rise precipitously needs to be increased, for clinicians prescribing venlafaxine, as well as those managing patients with glaucoma and ocular hypertension," the authors write.

More information: Full Text (subscription or payment may be required)