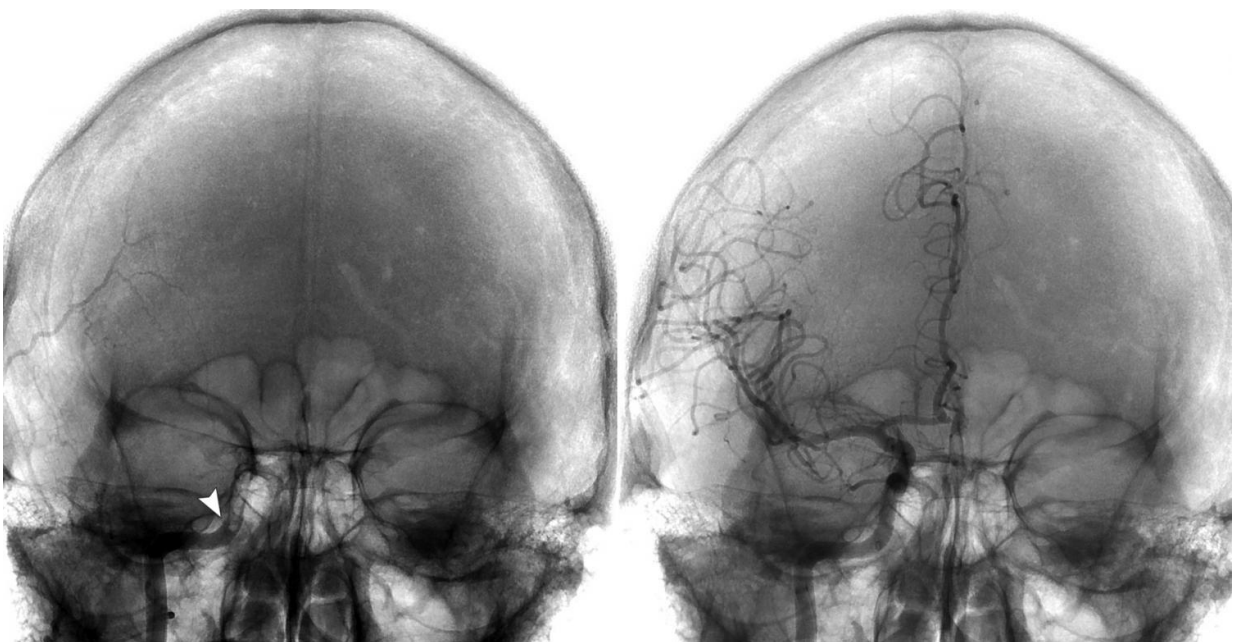


# New neuroendovascular technique shows promise in stroke patients with large-vessel clots

June 29 2016

---



Left: Frontal view of the skull showing occlusion of the right internal carotid artery (ICA) beginning at the level of the vertical petrous portion (arrow). Right: Frontal view of the skull after thrombectomy shows the revascularization of the ICA and the distal arteries supplying the right side of the brain. Credit: Medical University of South Carolina

In an article published online April 16, 2016 by the *Journal of Neurointerventional Surgery*, investigators at the Medical University of

South Carolina (MUSC) report promising 90-day outcomes for stroke patients with large-vessel clots who underwent thrombectomy or clot removal using the direct-aspiration, first pass technique (ADAPT). Approximately 58% of stroke patients with a large-vessel clot removed using the technique achieved a good outcome at 90 days, defined as a Modified Rankin Score (mRS) of 0 to 2.

ADAPT aims to remove the clot in its entirety with a large-diameter aspiration catheter in a single pass. In contrast, stent retrievers, currently considered standard of care, frequently fragment the clot for removal and can require several passes.

ADAPT was developed by MUSC Health neuroendovascular surgeons M. Imran Chaudry, M.D., Alejandro M. Spiotta, M.D., Aquilla S. Turk, D.O., and Raymond D. Turner, M.D., all co-authors on the April 2016 *Journal of Neurointerventional Surgery* article. MUSC Health neurosurgery resident Jan Vargas, M.D., is first author on the article.

"The goal in ADAPT is to take the largest-bore catheter available up to the blood clot and put suction where it's blocked and pull it out of the head to reestablish flow in that blood vessel," said Turk. If the first-pass attempt is unsuccessful, stent retrievers can still be used to remove the clot.

In the article, the investigators report the results of a retrospective study of 191 consecutive patients with acute ischemic stroke who underwent ADAPT at MUSC Health. In 94.2% of patients, blood vessels were successfully opened—by direct aspiration alone in 145 cases and by the additional use of stent retrievers in another 43 cases. Good outcomes at 90 days (mRS, 0-2) were achieved in 57.7% of patients who were successfully revascularized with aspiration alone and in 43.2% of those who also required a stent retriever. The average time required to reopen the blocked blood vessels was 37.3 minutes—29.6 minutes for direct

aspiration alone and 61.4 minutes for cases that also required stent retrievers. Patients presented for thrombectomy on average 7.8 hours after stroke onset.

These results confirm the promise of ADAPT, which was first described by the MUSC Health team in a seminal 2014 article in the *Journal of Neurointerventional Surgery*. Since the publication of that article, a number of single-center series studies have reported impressive recanalization times (the time it takes to open the blood vessel) and good neurological outcomes with ADAPT using a large-bore catheter, suggesting that it could offer an alternative approach to stent retrievers for mechanical thrombectomy.

Stent retrievers have been considered standard of care for stroke patients since the publication in the October 2015 issue of *Stroke* of a scientific statement on thrombectomy by the American Heart Association. That statement recommended rapid clot removal in addition to tissue plasminogen activator (tPA), a clot-busting drug that can minimize stroke complications if administered in a tight time window. The recommendation was based on the promising findings of five large clinical trials comparing treatment with tPA alone versus treatment with tPA plus thrombectomy using stent retrievers in large-vessel clots: MR CLEAN, EXTEND-IA, ESCAPE, SWIFT PRIME, and REVASCAT.

A definitive answer as to whether ADAPT could likewise become standard of care for stroke patients with large-vessel clots will require clinical trials comparing the efficacy of the direct aspiration technique versus stent retrievers in this population of [stroke patients](#).

The MUSC Health neuroendovascular surgery team is currently running the COMPASS trial (COMPARison of ASpiration vs Stent retriever as first-line approach; Clinicaltrials.gov identifier NCT02466893) in conjunction with colleagues Dr. J. Mocco of Mount Sinai and Dr. Adnan

Siddiqui of the University of Buffalo. The trial is randomizing patients to either ADAPT or a stent retriever as the initial thrombectomy technique. The trial, scheduled to enroll 270 patients, has enrolled 90 patients in the past year at ten sites in the United States.

**More information:** Jan Vargas et al, Long term experience using the ADAPT technique for the treatment of acute ischemic stroke, *Journal of NeuroInterventional Surgery* (2016). [DOI: 10.1136/neurintsurg-2015-012211](https://doi.org/10.1136/neurintsurg-2015-012211)

Provided by Medical University of South Carolina

Citation: New neuroendovascular technique shows promise in stroke patients with large-vessel clots (2016, June 29) retrieved 25 April 2024 from <https://medicalxpress.com/news/2016-06-neuroendovascular-technique-patients-large-vessel-clots.html>

This document is subject to copyright. Apart from any fair dealing for the purpose of private study or research, no part may be reproduced without the written permission. The content is provided for information purposes only.