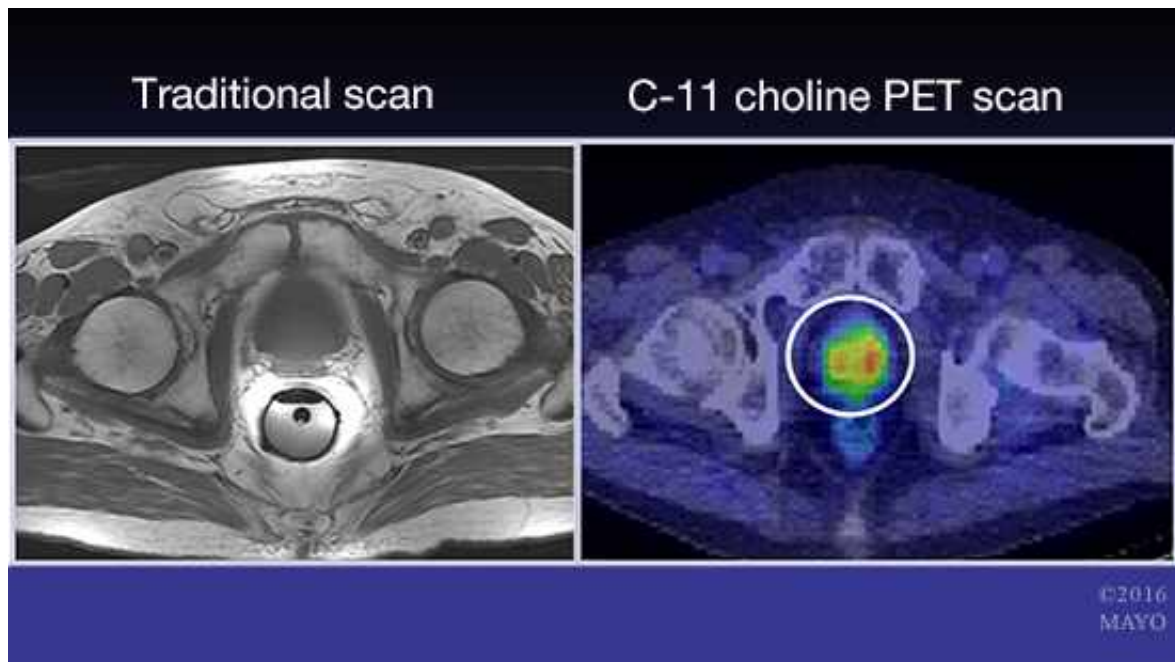


Researchers map prostate cancer relapse using C-11 choline PET and MRI

October 5 2016



Credit: Mayo Clinic

A team of Mayo Clinic researchers has, for the first time, successfully mapped patterns of prostate cancer recurrence, following surgery. Using C-11 choline PET imaging and multiparametric MRI, researchers found an anatomically diverse pattern of recurrence, which may help optimize treatment of patients whose prostate cancer returns after surgery. The research findings are published today in the *Journal of Urology*.

"This study has important implications for men who have a rising prostate-specific antigen (PSA) test, also known as biochemical recurrence, after radical prostatectomy for prostate cancer," says Jeffrey Karnes, M.D., a urological surgeon at Mayo Clinic. "In men with biochemical recurrence, determining where the disease has recurred is quite challenging, especially when the PSA level is low."

According to Dr. Karnes, in the U.S., approximately 30 percent of patients who have had an initial prostate cancer surgically excised will suffer a recurrence and seek treatment. "Current imaging tests like conventional bone and CT scans are not sensitive enough to identify sites of recurrence, especially when the PSA value is lower than 10," he says.

Dr. Karnes says the combination of C-11 choline PET scanning and multiparametric MRI, helps physicians accurately identify sites of recurrence at an average PSA of 2. More importantly, he says, "This type of staging allows us to identify sites of recurrent disease that can be potentially treated either surgically or with radiation."

Dr. Karnes and his team also were able to describe patterns of [prostate cancer](#) recurrence. They found that nearly two-thirds of men in the study had recurrence limited to the pelvis, which potentially can be targeted for radiation therapy.

More information: Ilya Sobol et al. Contemporary Mapping of Post-Prostatectomy Prostate Cancer Relapse with C-11 Choline PET and Multiparametric MRI, *The Journal of Urology* (2016). [DOI: 10.1016/j.juro.2016.07.073](https://doi.org/10.1016/j.juro.2016.07.073)

Provided by Mayo Clinic

Citation: Researchers map prostate cancer relapse using C-11 choline PET and MRI (2016, October 5) retrieved 3 May 2024 from <https://medicalxpress.com/news/2016-10-prostate-cancer-relapse-c-choline.html>

This document is subject to copyright. Apart from any fair dealing for the purpose of private study or research, no part may be reproduced without the written permission. The content is provided for information purposes only.