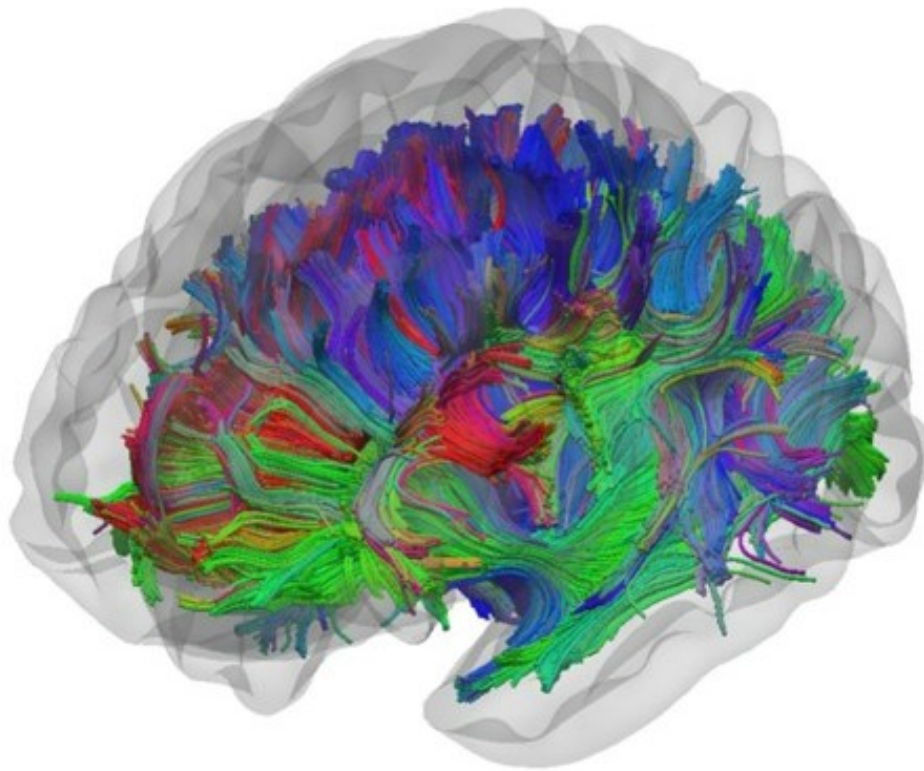


Epilepsy – why do seizures sometimes continue after surgery?

November 17 2016



White matter tracts. Credit: University of Liverpool

New research from the University of Liverpool, published in the journal *Brain*, has highlighted the potential reasons why many patients with severe epilepsy still continue to experience seizures even after surgery.

Epilepsy continues to be a serious health problem and is the most common serious neurological disorder. Medically intractable [temporal lobe epilepsy](#) (TLE) remains the most frequent neurosurgically treated epilepsy disorder.

Many people with this condition will undergo a temporal lobe resection which is a surgery performed on the brain to control [seizures](#). In this procedure, brain tissue in the temporal lobe is resected, or cut away, to remove the seizure focus.

Unfortunately, approximately one in every two patients with TLE will not be rendered completely seizure free after temporal lobe surgery, and the reasons underlying persistent [postoperative](#) seizures have not been resolved.

Reliable biomarkers

Understanding the reasons why so many patients continue to experience postoperative seizures, and identifying reliable biomarkers to predict who will continue to experience seizures, are crucial clinical and scientific research endeavours.

Researchers from the University's Institute of Translational Medicine, led by Neuroimaging Lead Dr Simon Keller and collaborating with Medical University Bonn (Germany), Medical University of South Carolina (USA) and King's College London, performed a comprehensive [diffusion tensor imaging](#) (DTI) study in patients with TLE who were scanned preoperatively, postoperatively and assessed for postoperative seizure outcome.

Diffusion tensor imaging (DTI) is a MRI-based neuroimaging technique that provides insights into brain network connectivity.

The results of these scans allowed the researchers to examine regional tissue characteristics along the length of temporal lobe white matter tract bundles. White matter is mainly composed of axons of nerve cells, which form connections between various grey matter areas of the brain, and carry nerve impulses between neurons allowing communication between different brain regions.

Through their analysis the researchers could determine how abnormal the white matter tracts were before surgery and how the extent of resection had affected each tract from the postoperative MRI scans.

Surgery outcomes

The researchers identified preoperative abnormalities of two temporal lobe white matter tracts that are not included in standardised temporal lobe surgery in patients who had postoperative seizures but not in patients with no seizures after surgery.

The two tracts were in the 'fornix' area on the same side as surgery, and in the white matter of the 'parahippocampal' region on the opposite side of the brain.

The tissue characteristics of these white matter tracts enabled researchers to correctly identify those likely to have further seizures in 84% of cases (sensitivity) and those unlikely to have further seizures in 89% of cases (specificity). This is significantly greater than current estimates.

The researchers also found that a particular temporal lobe white matter tract called the 'uncinate fasciculus' was abnormal – and potentially involved in the generation of seizures – in patients with excellent and suboptimal postoperative outcomes.

However, it was found that significantly more of this tract was surgically resected/removed in the patients with an excellent outcome.

New insights

Dr Simon Keller, said: "There is scarce information on the prediction of postoperative seizure outcome using preoperative imaging technology, and this study is the first to rigorously investigate the tissue characteristics of temporal lobe [white matter](#) tracts with respect to future seizure classifications.

"Although there is some way to go before this kind of data can influence routine clinical practice, these results may have the potential to be developed into imaging prognostic markers of postoperative outcome and provide new insights for why some [patients](#) with [temporal lobe](#) epilepsy continue to experience postoperative seizures."

More information: Simon S. Keller et al. Preoperative automated fibre quantification predicts postoperative seizure outcome in temporal lobe epilepsy, *Brain* (2016). [DOI: 10.1093/brain/aww280](https://doi.org/10.1093/brain/aww280)

Provided by University of Liverpool

Citation: Epilepsy – why do seizures sometimes continue after surgery? (2016, November 17) retrieved 20 April 2024 from <https://medicalxpress.com/news/2016-11-epilepsy-seizures-surgery.html>

This document is subject to copyright. Apart from any fair dealing for the purpose of private study or research, no part may be reproduced without the written permission. The content is provided for information purposes only.