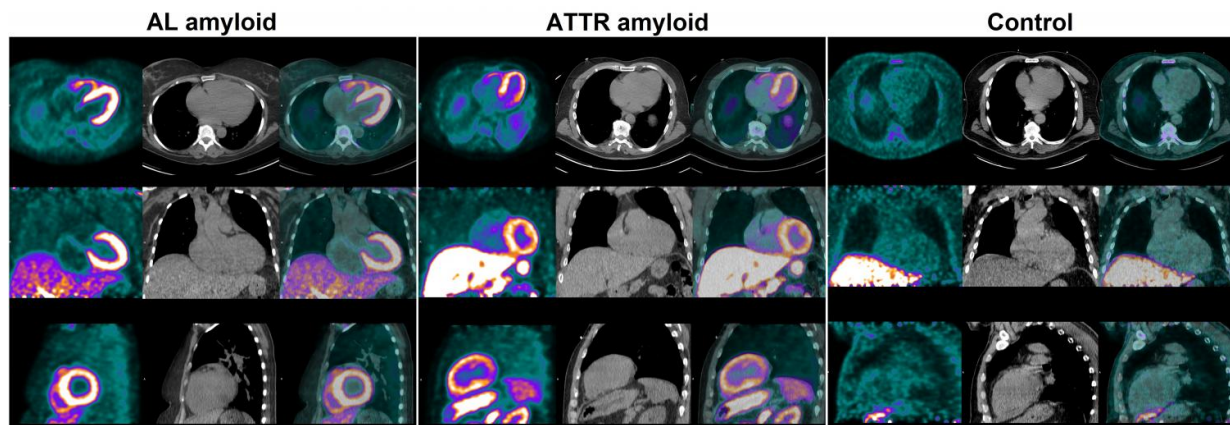


# PET imaging visualizes hard-to-diagnose cardiac amyloidosis

November 1 2016



In a pilot study, F-18-florbetaben PET imaging appeared promising for differentiating between cardiac amyloidosis and hypertensive heart disease. Credit: W. Phillip Law/Princess Alexandra Hospital, Brisbane, Australia

Researchers at Princess Alexandra Hospital, Brisbane, Australia, have demonstrated that cardiac amyloidosis (abnormal deposits of proteins in the heart), which is notoriously difficult to diagnose, can be visualized noninvasively with positron emission tomography (PET) using the radiotracer fluorine-18 (F-18)-florbetaben. The study is published in the November issue of *"The Journal of Nuclear Medicine."*

Amyloidosis eventually leads to dysfunction of the affected organs. When the heart is affected, the prognosis is extremely poor. Dr W.

Phillip Law, the corresponding author of the study, explains, "The first signs and symptoms of the disease are nonspecific and usually attributed to other conditions. Currently, there is no definitive test to diagnose cardiac amyloidosis other than an invasive biopsy of the heart muscle. Cardiac amyloidosis is often not diagnosed until late in the course of the disease, as the typical appearance of the infiltrated myocardium on echocardiography and MRI can be mistaken for other more prevalent disorders."

While previous research of amyloid radiotracers in the heart has used normal subjects as controls, this study compared subjects with thickened heart muscle secondary to amyloid deposition to those with thickened myocardium due to hypertensive heart disease.

Being able to visualize and quantify [amyloid deposition](#) in heart muscle may provide an accurate and noninvasive means of diagnosing the disorder and also may be useful in monitoring disease burden.

F-18-florbetaben PET was performed in 14 subjects. Target-to-background standardized uptake values (SUV) ratio and percentage myocardial radiotracer retention were higher in amyloid patients compared to hypertensive control subjects. A cut-off value of 40 percent was able to differentiate between cardiac amyloid patients and hypertensive control subjects.

The study shows that F-18-florbetaben PET imaging can accurately identify and differentiate between cardiac amyloidosis and hypertensive heart disease. Percentage myocardial F-18-florbetaben retention was an independent determinant of myocardial dysfunction in cardiac amyloidosis.

Looking ahead, Dr Law envisions, "Tailored molecular imaging with PET using florbetaben may significantly simplify the diagnostic

algorithm for patients with suspected cardiac amyloidosis. Future studies investigating florbetaben uptake pattern in other [non-amyloid, non-hypertensive] causes of [heart muscle](#) thickening would further clarify the specificity of florbetaben." He adds, "The relationship of PET quantification of florbetaben retention in the heart, with histological amyloid plaque burden, may provide another means of monitoring disease and could also be useful in monitoring response of cardiac amyloid to treatment, but further research needs to be undertaken to investigate this relationship."

**More information:** W. P. Law et al, Cardiac Amyloid Imaging with 18F-Florbetaben PET: A Pilot Study, *Journal of Nuclear Medicine* (2016). [DOI: 10.2967/jnumed.115.169870](https://doi.org/10.2967/jnumed.115.169870)

Provided by Society of Nuclear Medicine

Citation: PET imaging visualizes hard-to-diagnose cardiac amyloidosis (2016, November 1) retrieved 2 May 2024 from <https://medicalxpress.com/news/2016-11-pet-imaging-visualizes-hard-to-diagnose-cardiac.html>

This document is subject to copyright. Apart from any fair dealing for the purpose of private study or research, no part may be reproduced without the written permission. The content is provided for information purposes only.
---