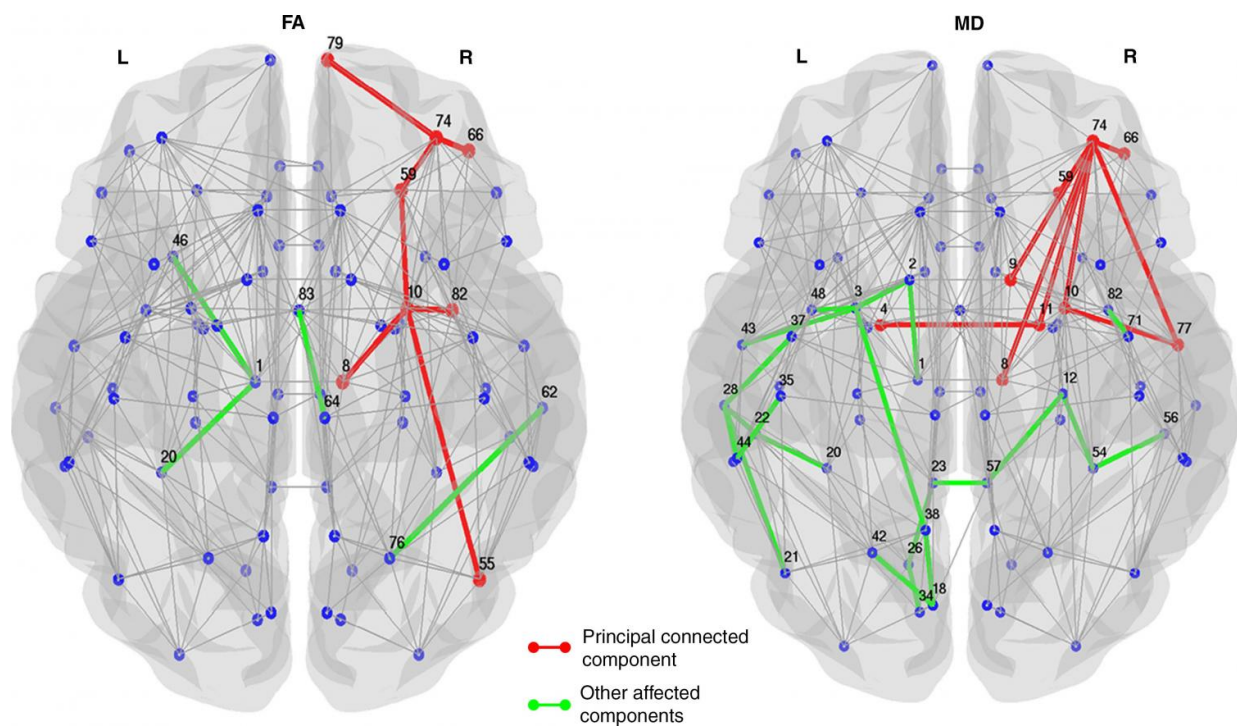


Imaging links structural brain changes and cognitive decline in Parkinson's

December 7 2016



Affected structural connections in patients with PD and MCI relative to healthy control subjects and patients with Parkinson disease (PD) without mild cognitive impairment (MCI). The principal connected component is shown in red, and the other affected connections not included in the principal connected component are shown in green. Subnetworks show altered structural connectivity (decreased fractional anisotropy or increased mean diffusivity) in patients with PD and MCI relative to healthy control subjects at P

People with Parkinson's disease and cognitive impairment have disruptions in

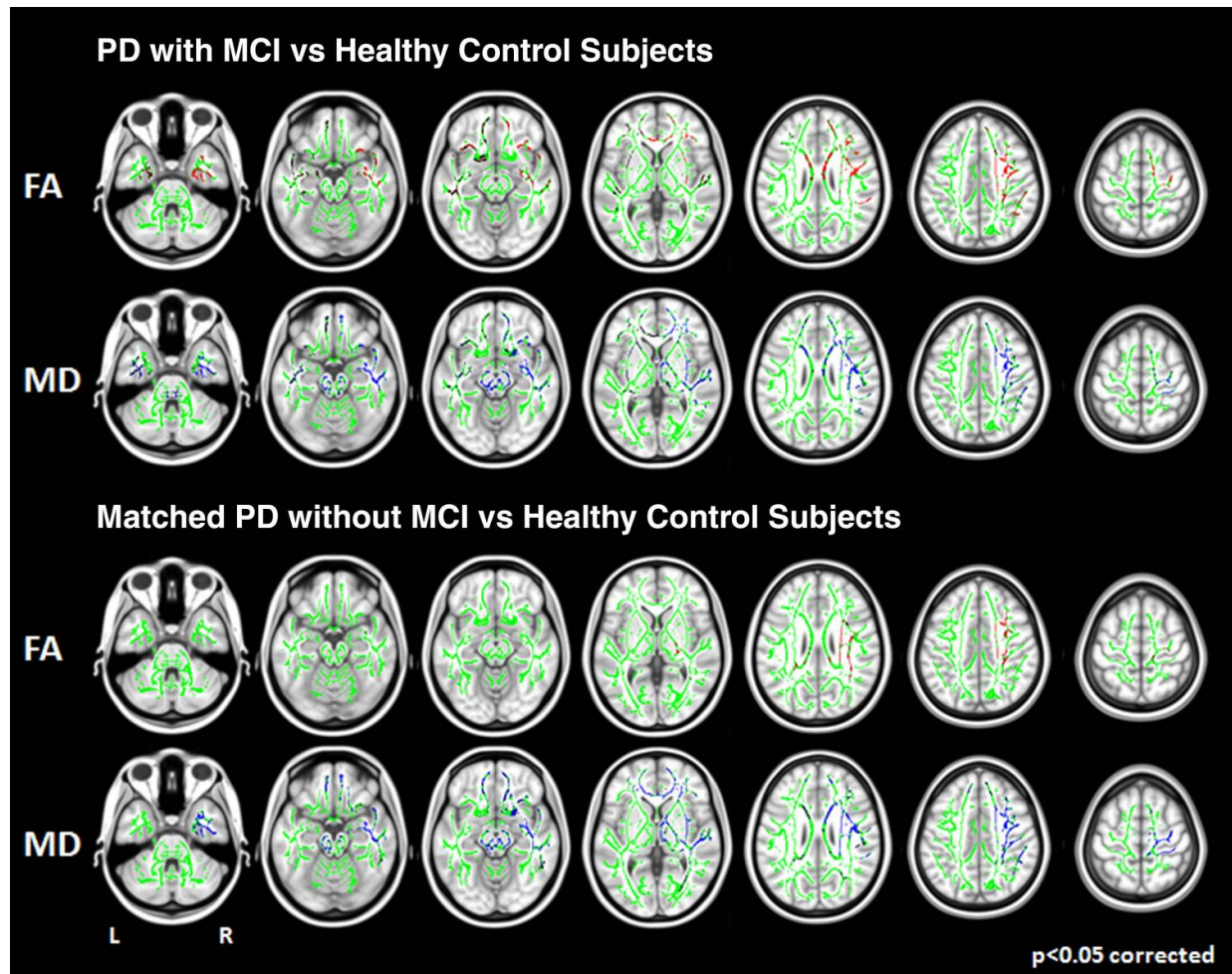
their brain networks that can be seen on a type of MRI, according to a study appearing online in the journal *Radiology*.

Parkinson's disease (PD) is a progressive disorder of the central nervous system characterized by tremors or trembling and stiffness in the limbs, impaired balance and coordination. It affects about 10 million people worldwide. As PD progresses, many patients develop [mild cognitive impairment](#) (MCI), a decline in cognitive abilities, including thinking, memory and language. MCI can be identified in approximately 25 percent of newly diagnosed PD patients, and patients with MCI progress to dementia more frequently than those with normal cognitive performance.

For the new study, lead investigator Massimo Filippi, M.D., from the Neuroimaging Research Unit at San Raffaele Scientific Institute in Milan, Italy, coauthors Federica Agosta, M.D., Ph.D., and Sebastiano Galantucci, M.D., and other colleagues used an MRI technique called diffusion tractography to look for differences in the neural networks of PD patients with and without MCI.

Increasingly, the [human brain](#) is understood as an integrated network, or connectome, that has both a structural and functional component. By applying an analytical tool called graph analysis to the imaging results, researchers can measure the relationships among highly connected and complex data like the network of connections in the human brain.

"Cognitive impairment in PD is one of the major non-motor complications of the disease, as well as one of the major concerns of patients and caregivers at the time of diagnosis," Dr. Agosta said. "Study of the changes related to cognitive impairment in PD is imperative in order to be able to answer patients' questions and finally be able to predict the future development of this condition."



MR images show microstructural white matter damage (tract-based spatial statistics). Areas of decreased fractional anisotropy (FA) (red) and increased mean diffusivity (blue) overlapped on the overall FA skeleton (green) in groups of patients with Parkinson disease compared with healthy control subjects (P

The study group was made up of 170 PD patients, including 54 with MCI and 116 without, and 41 healthy controls. Analysis of imaging results showed that only PD patients with MCI had significant alterations at the brain network level. Measurements of the movement and diffusion of water in the brain, an indicator of the condition of the brain's signal-carrying white matter, differentiated PD patients with MCI from healthy controls and non-MCI PD patients with a good accuracy. Researchers said the results show that cognitive impairment in PD is likely the consequence of a disruption of complex structural [brain networks](#) rather than degeneration of individual white matter bundles.

The results may offer markers to differentiate PD patients with and without cognitive

deficits, according to Dr. Agosta.

"If confirmed and replicated by other studies, these results would suggest the use of MRI in PD to support the clinicians in monitoring the disease and predicting the occurrence of cognitive complications," she said.

The researchers have obtained resting state functional MRI data from the patients and plan to study the functional connectome alterations associated with [cognitive impairment](#) in PD and how structural and functional abnormalities are interrelated.

The study is part of an international collaboration between the San Raffaele Scientific Institute and the Clinic of Neurology at the University of Belgrade in Belgrade, Serbia, led by Vladimir Kostic, M.D.

Provided by Radiological Society of North America

Citation: Imaging links structural brain changes and cognitive decline in Parkinson's (2016, December 7) retrieved 30 April 2024 from <https://medicalxpress.com/news/2016-12-imaging-links-brain-cognitive-decline.html>

<p>This document is subject to copyright. Apart from any fair dealing for the purpose of private study or research, no part may be reproduced without the written permission. The content is provided for information purposes only.</p>
--