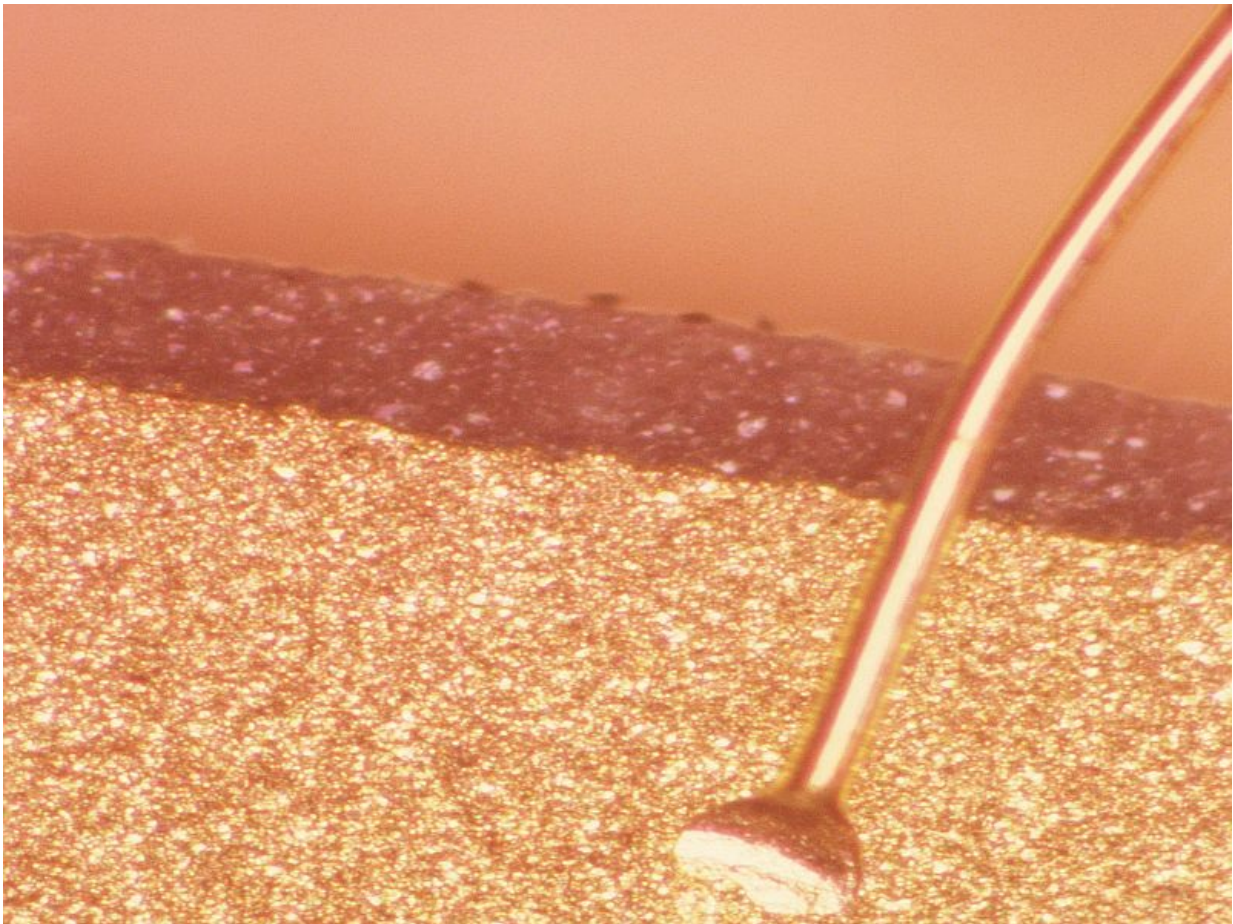


Thulium fiber laser rejuvenates male scalp with photodamage

January 30 2017



(HealthDay)—For men with extensive photodamage of the scalp, one

session of fractionated 1,927 nm thulium fiber laser can achieve rejuvenation, according to a study published online Jan. 24 in *Lasers in Surgery and Medicine*.

Monica Boen, M.D., from the University of Illinois at Chicago, and colleagues examined the safety and efficacy of one treatment of fractionated 1,927 nm thulium fiber laser using high density and high energy settings in four [male patients](#) with Fitzpatrick skin types II to III and extensive photodamage of the scalp.

The researchers found that the patients experienced 60 to 90 percent improvement in dyspigmentation, lentigines, and keratosis. There were no [adverse events](#), and the procedure was well tolerated.

"This case series is the first report in the literature demonstrating the successful rejuvenation of the [scalp](#) using the 1,927 nm thulium fiber laser," the authors write.

More information: [Full Text \(subscription or payment may be required\)](#)

Copyright © 2017 [HealthDay](#). All rights reserved.

Citation: Thulium fiber laser rejuvenates male scalp with photodamage (2017, January 30) retrieved 12 May 2024 from <https://medicalxpress.com/news/2017-01-thulium-fiber-laser-rejuvenates-male.html>

<p>This document is subject to copyright. Apart from any fair dealing for the purpose of private study or research, no part may be reproduced without the written permission. The content is provided for information purposes only.</p>
--