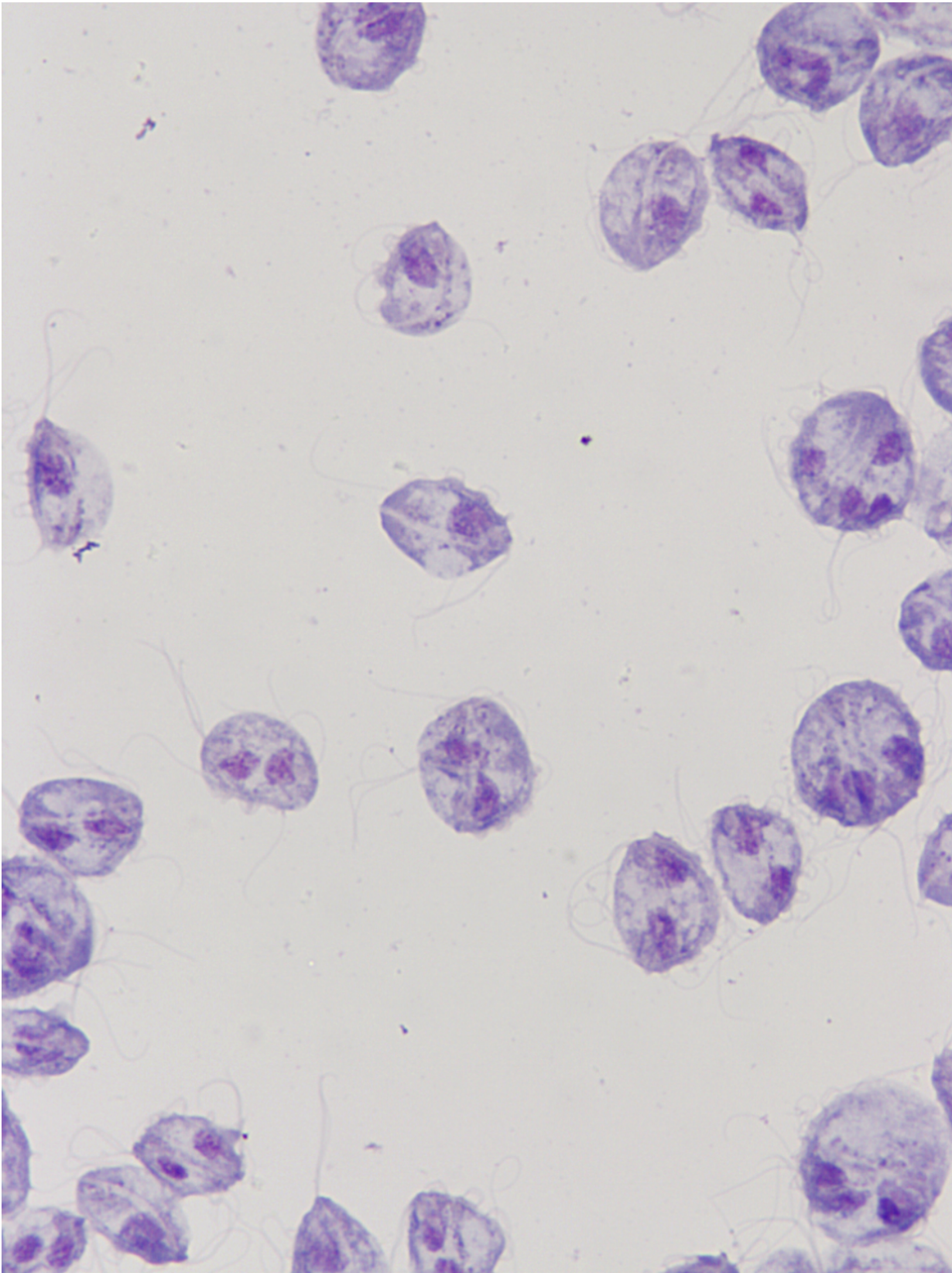


Trichomonosis: A conundrum in cats

March 20 2017



These tear-drop shaped, highly motile flagellates lack many of their own biosynthetic pathways and rely on the salvage of nutrients from their host for survival. Credit: Jody Gookin

Over the past two decades, the protozoan *Tritrichomonas foetus* has come to be recognised as a cause of chronic colitis in cats in many countries worldwide. Today trichomonosis is regarded as one of the most common infectious causes of large bowel diarrhea. Affected cats are usually young (median age 1 year), and maintain good health and body condition, but they exhibit a waxing and waning diarrhea. Characteristically, faeces are 'cow pie' in consistency and often contain mucus and/or blood. In many cats, the diarrhea will spontaneously resolve without treatment after several months, but in some cases it continues to wax and wane for many years.

The culprit, *T. foetus*, a tear-drop shaped, highly motile flagellate, is thought to be transmitted from cat to cat via the faecal-oral route; [cats](#) acquired from breeding catteries and shelters are at increased risk of [infection](#), as dense housing conditions favour this route of transmission. *T. foetus* also infects cattle, in which it is sexually transmitted and a potential cause of abortion and infertility. The economic impact of the disease for the cattle industry around the world has given rise to a rapidly developing field of research into trichomonads. Frustratingly for veterinarians, however, the more that has been learnt about trichomonosis in cats, the trickier it has become.

The complications and controversies surrounding feline trichomonosis are explored in a state-of-the-art review article published this month in the Journal of Feline Medicine and Surgery. The authors, Dr Jody Gookin and colleagues at the College of Veterinary Medicine, North Carolina State University explain that one of the most pressing

challenges is that feline trichomonosis is resistant to all commonly used antiprotozoals. Currently, the only drug that has been demonstrated to be effective in cats is ronidazole, but this agent has a narrow safety margin and clinical resistance is increasingly recognized. A cat treated with the drug may indeed go on to show complete, or almost complete, resolution of their [diarrhea](#), but it can be very difficult to determine whether the treatment has truly eradicated the infection or simply concealed the clinical signs. This, in turn, raises the specific question of what risk a treated cat may pose to other cats if, say, being reintroduced into a breeding cattery. More broadly, given these difficulties, and the spontaneous resolution of diarrhea seen in many cats, the controversial question has arisen: should veterinarians even bother treating the infection in cats?

The authors conclude that, while research has come a long way in advancing understanding of this infection, there remain many unanswered questions that are pivotal to future progress. Are feline and bovine *T. foetus* genotypes truly biologically distinct, residing in separate hosts, or is there the potential for cross-infection between cattle and cats? Should all cats in contact with a *Tritrichomonas* species infected cat also be treated? What is the long-term effect of *Tritrichomonas* species infection on feline gastrointestinal health, and can safer and more effective drugs for treatment of the infection be identified?

More information: Jody L Gookin et al. The conundrum of feline trichomonosis, *Journal of Feline Medicine and Surgery* (2017). [DOI: 10.1177/1098612X17693499](https://doi.org/10.1177/1098612X17693499)

Provided by SAGE

Citation: Trichomonosis: A conundrum in cats (2017, March 20) retrieved 25 April 2024 from

<https://medicalxpress.com/news/2017-03-trichomonosis-conundrum-cats.html>

This document is subject to copyright. Apart from any fair dealing for the purpose of private study or research, no part may be reproduced without the written permission. The content is provided for information purposes only.