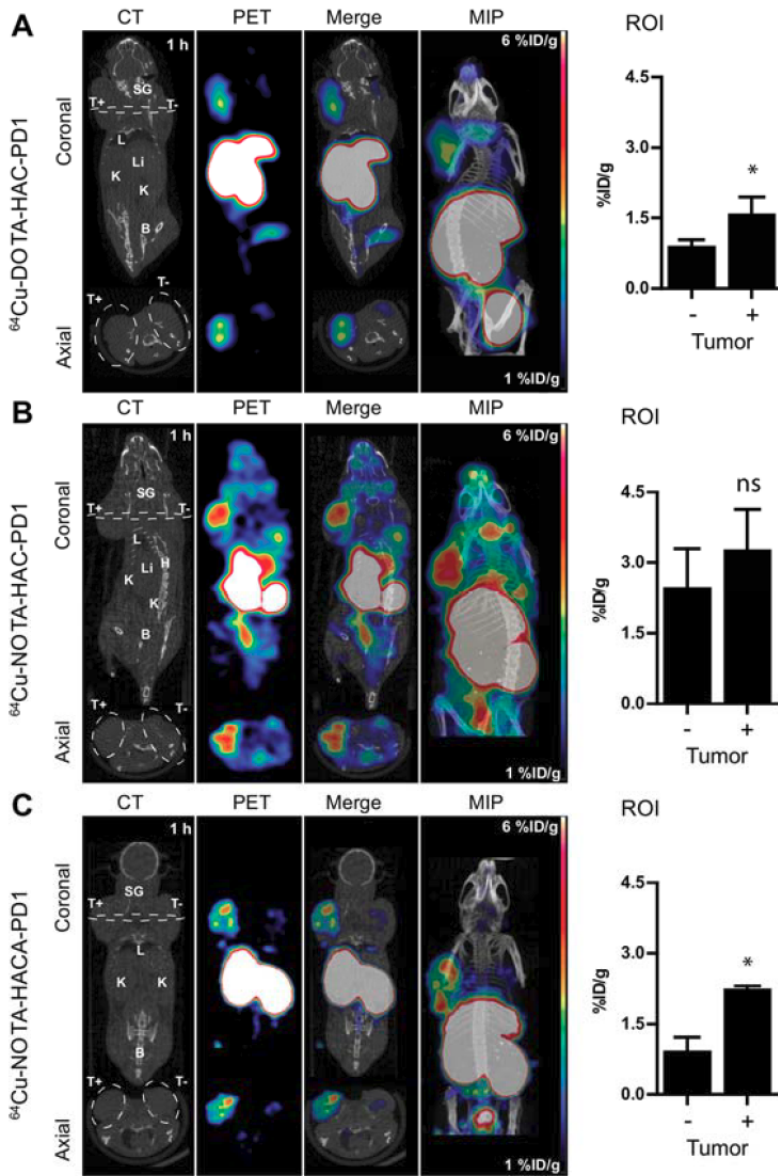


PET radiotracer design for monitoring targeted immunotherapy

April 7 2017



Comparison of (A) Cu-64-DOTA-HACPD1, (B) Cu-64-NOTA-HAC-PD1, and (C) Cu-64-NOTA-HACA-PD1 ImmunoPET images acquired at 1h p.i. (~1.85 MBq/10 μ g/200 μ l) of NSG mice bearing dual subcutaneous tumors in shoulders (right = hPD-L1+; left = hPD-L1-). Panels left to right show representative coronal and axial cross sections of CT, PET, and merged PET/CT images with maximum intensity projection (MIP). White dashed line, coronal image, demarcation of axial cross-section; White dashed line, axial image, tumor boundary. SG, salivary gland; T+, hPD-L1 positive tumor; T-, hPD-L1 negative tumor; L, lung; Li, liver; K, kidney; B, bladder; H, heart. Scale bars represent 1 percent (blue) - 6 percent (red) ID/g. Tumor uptake was quantified using ROI analysis (right panel) without partial volume correction. Error bars represent SD. ns, not significant; *p

Citation: PET radiotracer design for monitoring targeted immunotherapy (2017, April 7) retrieved 25 April 2024 from <https://medicalxpress.com/news/2017-04-pet-radiotracer-immunotherapy.html>

This document is subject to copyright. Apart from any fair dealing for the purpose of private study or research, no part may be reproduced without the written permission. The content is provided for information purposes only.