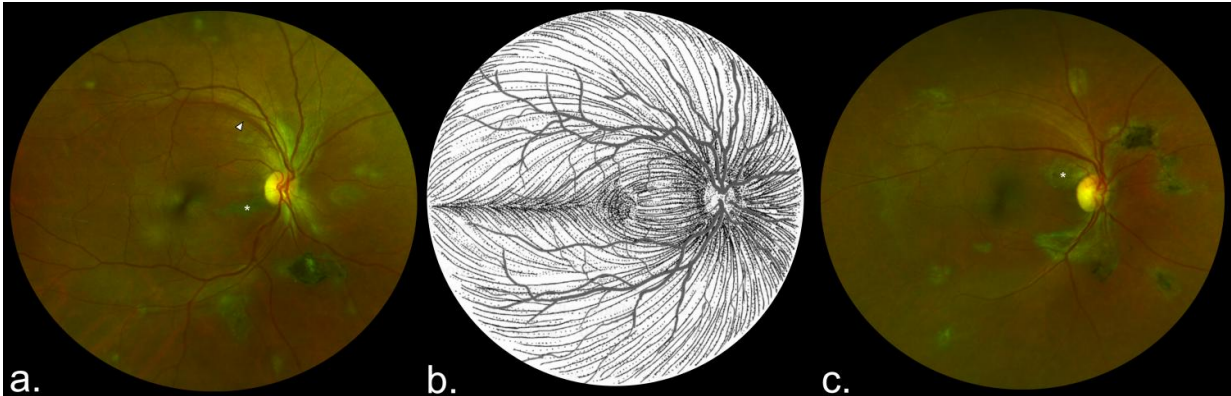


Ebola survivors have a 'unique' retinal scar

May 15 2017



These are composite scanning laser ophthalmoscope retinal images showing type 6 Ebola peripapillary or peripheral lesions, observed following the anatomic distribution of the ganglion cell axon (retinal nerve fiber layer), in a case-control study of ocular signs in Ebola virus disease survivors, Sierra Leone, 2016. A) Example 1, right eye. B) Illustration of the ganglion cell axon anatomic distribution. Courtesy of W.L.M. Alward. C) Example 2, right eye. Asterisks indicate curvilinear lesions distinct from the retinal vasculature. White arrowhead indicates retinal nerve fiber wedge defect. Credit: University of Liverpool

Researchers from the University of Liverpool have conducted a study of Ebola survivors to determine if the virus has any specific effects on the back on the eye using an ultra widefield retinal camera.

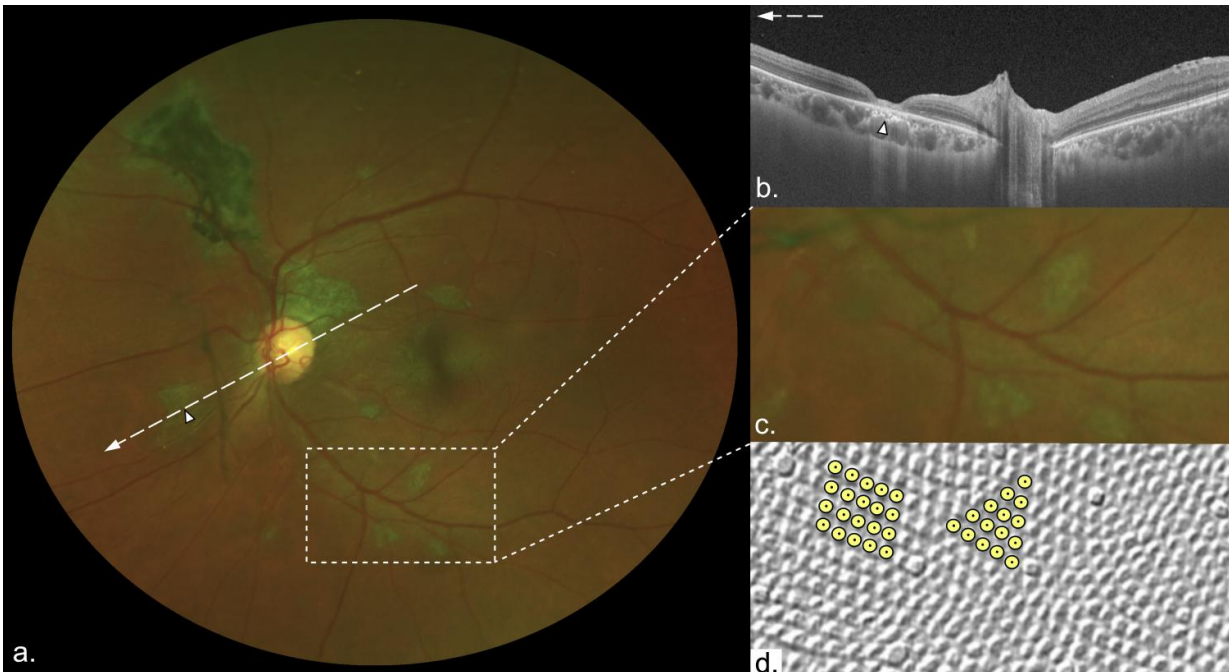
To find out more about the broad-ranging symptoms of Post Ebola Syndrome (PES), a clinical research team led by Dr Janet Scott and Dr

Calum Semple, from the University's Institute of Translational Medicine, assessed survivors discharged from the Ebola Treatment Unit at the 34th Regiment Military Hospital in Freetown, Sierra Leone.

Two years on from the Ebola outbreak in West Africa, and many Ebola survivors are still presenting with symptoms of post-Ebola syndrome (PES), including joint and muscle pains and psychiatric and neurological problems.

Hiding viruses

Viruses, like Ebola, can stay hidden in our bodies by exploiting a vulnerability in our immune systems. This vulnerability is called "immune privilege," and comes from an old observation that foreign tissue transplanted into certain parts of the body don't elicit the usual immune response. This includes the brain, spinal cord, and eyes. Scientists believe this is because the brain, spinal cord, and eyes are simply too delicate and important to withstand the inflammation that's typical of an [immune response](#).



These are characteristic features of lesions observed in a case-control study of ocular signs in Ebola virus disease survivors, Sierra Leone, 2016. A) Composite scanning laser ophthalmoscope retinal image, left eye. Arrow indicates direction of the optical coherence tomography scan. B) Optical coherence tomography. White, long, dashed line indicates cross-sectional plane; white arrowhead indicates Ebola lesion limited to the retinal layers with an intact retinal pigment epithelium. Magnified 1.5× from original image (panel A). C) Examples of straight-edged, sharp angulated lesions (magnified from panel A). D) Example of tangential section through the human fovea with illustrative highlighting of a triangular photoreceptor matrix corresponding to Ebola lesional shape. Courtesy of Ahnelt et al. Credit: University of Liverpool

An eye team led by Dr Paul Steptoe, compared eye examinations of PES sufferers in Sierra Leone and the control population. A total of 82 Ebola survivors who had previously reported ocular symptoms and 105 unaffected controls from civilian and military personnel underwent ophthalmic examination, including widefield retinal imaging.

The results of the research, which has been published in the *Emerging Infectious Diseases* journal, shows that around 15% of Ebola survivors examined have a retinal scar that appears specific to the disease.

Reduced vision

Dr Steptoe, said: "The distribution of these retinal scars or lesions provides the first observational evidence that the virus enters the eye via the optic nerve to reach the retina in a similar way to West Nile Virus. Luckily, they appear to spare the central part of the eye so vision is preserved. Follow up studies are ongoing to assess for any potential recurrence of Ebola eye disease.

"Our study also provides preliminary evidence that in survivors with cataracts causing reduced vision but without evident active eye inflammation (uveitis), aqueous fluid analysis does not contain Ebola [virus](#) therefore enabling access to cataract surgery for survivors."

More information: Paul J. Steptoe et al, Novel Retinal Lesion in Ebola Survivors, Sierra Leone, 2016, *Emerging Infectious Diseases* (2017). [DOI: 10.3201/eid2307.161608](https://doi.org/10.3201/eid2307.161608)

Provided by University of Liverpool

Citation: Ebola survivors have a 'unique' retinal scar (2017, May 15) retrieved 9 April 2024 from <https://medicalxpress.com/news/2017-05-ebola-survivors-unique-retinal-scar.html>

This document is subject to copyright. Apart from any fair dealing for the purpose of private study or research, no part may be reproduced without the written permission. The content is provided for information purposes only.
