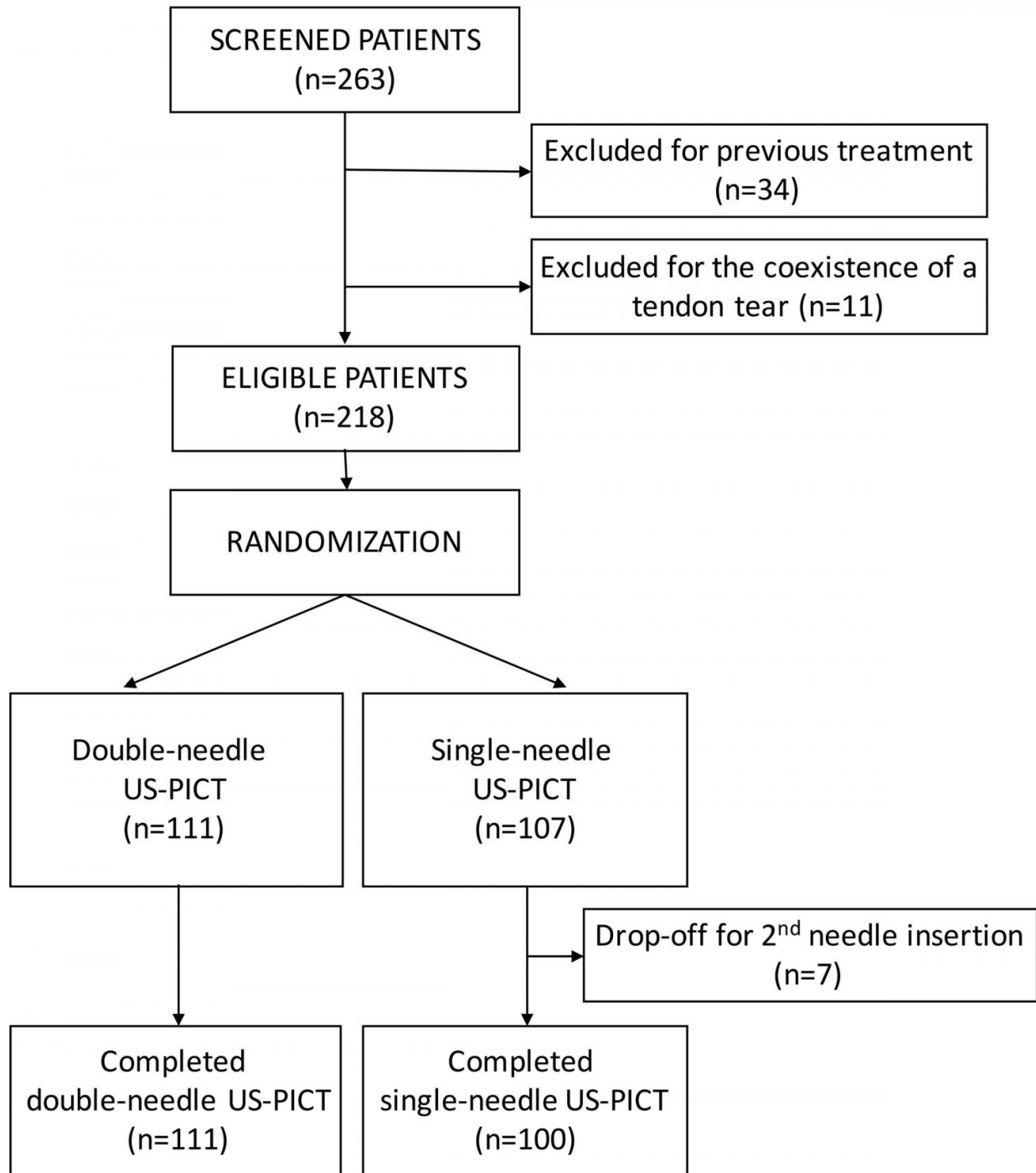


Study looks at needles in treatment for shoulder pain

June 14 2017



Flowchart of study population. US-PICT = ultrasonography-guided percutaneous irrigation of calcific tendinopathy. Credit: Radiological Society of North America

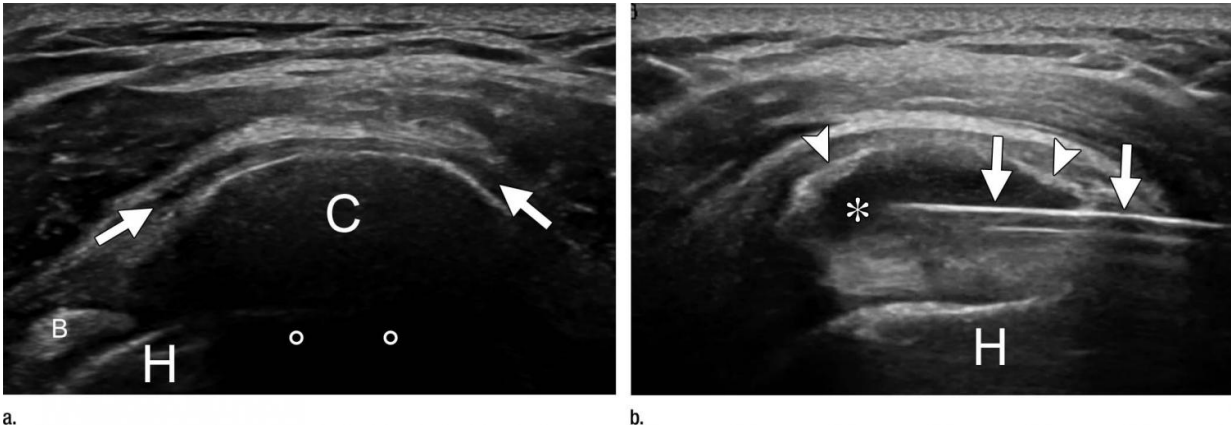
According to a new study published online in the journal *Radiology*, the type of procedure used to treat shoulder calcifications should be tailored to the type of calcification. The results of the study will help interventional radiologists determine whether to use one or two needles for an ultrasound-guided treatment for a common condition called rotator cuff calcific tendinopathy.

Calcific tendinopathy is a condition in which [calcium](#) deposits form on the tendons of the [rotator cuff](#), a group of four tendons that stabilizes the shoulder joint. The condition, which occurs in approximately 20 percent of painful shoulders, causes pain and tenderness ranging from low-grade to highly disabling.

"There is still no consensus on how to treat calcific tendinopathy," said researcher Luca Maria Sconfienza, M.D., Ph.D., associate professor at the University of Milan and chair of the Department of Radiology at the IRCCS Istituto Ortopedico Galeazzi. "However, ultrasound-guided percutaneous irrigation is widely performed throughout the world and is currently the first-line treatment for the condition, because it is quick, minimally invasive and has a low complication rate."

The procedure involves injecting a fluid such as saline solution into the tendon to dissolve the calcium deposits and then extracting the calcium-filled solution.

"The main difference among ultrasound percutaneous irrigation procedures is the use of one or two needles," Dr. Sconfienza said. "Until now, a direct comparison of one versus two needles has never been performed."

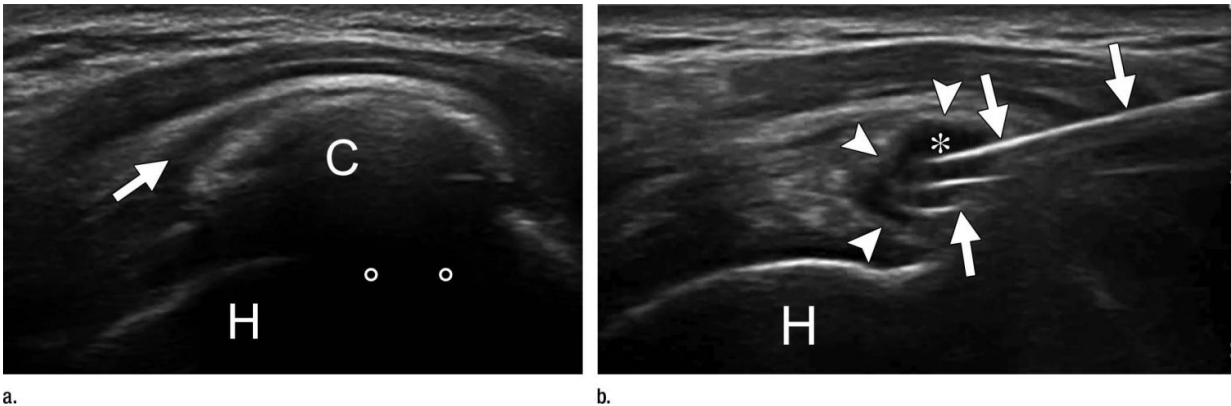


US images show supraspinatus calcification in a 29-year-old woman. (a) Calcific deposit (C) can be clearly seen with moderate acoustic shadowing (circles). Subacromial bursitis (arrows) can be seen. (b) End of treatment. Most calcific material was removed from calcification (?) with single-needle procedure. Only a thin calcific wall (arrowheads) was left. Needle (arrows) is still inside calcification. B = biceps tendon, H = humeral head. Credit: Radiological Society of North America

The study included 211 patients (77 men and 134 women between the ages of 24 and 69) who underwent ultrasound percutaneous irrigation between 2012 and 2014. The patients were randomly assigned to have the one-[needle](#) or the two-needle procedure.

Ultrasound exams were performed on each patient to identify the exact location of calcium deposits in the tendons and whether the deposit appeared to be hard or fluid. For patients in the double-needle procedure group, 16-gauge needles were inserted inside the [calcification](#) under continuous ultrasound monitoring, and the area was flushed with injections and extractions of saline until the tendon was free of visible calcium. The single-needle procedure utilized an 18-gauge needle for the injection and extraction.

"Procedure times were shorter and the calcium dissolution was easier when using two needles for hard calcifications and one needle for fluid calcifications," Dr. Sconfienza said.



US images show supraspinatus calcification in a 37-year-old man. (a) Calcific deposit (C) can be clearly seen with moderate acoustic shadowing (circles). Subacromial bursitis (arrow) can be seen. (b) End of treatment. Most calcific material was removed from calcification (?) with double-needle procedure. Only a thin calcific wall (arrowheads) was left. Needles (arrows) are still inside calcification. H = humeral head. Credit: Radiological Society of North America

"In terms of clinical outcomes after one year of follow-up, there was no significant difference between single- and double-needle ultrasound-guided irrigation," he added.

At one-year follow-up, no residual or new calcifications or tendon tears at the site of the initial [calcium deposits](#) were detected.

More information: "Rotator Cuff Calcific Tendinopathy: Randomized Comparison of US-guided Percutaneous Treatments by Using One or Two Needles." *Radiology* (2017).

Provided by Radiological Society of North America

Citation: Study looks at needles in treatment for shoulder pain (2017, June 14) retrieved 20 March 2024 from

<https://medicalxpress.com/news/2017-06-needles-treatment-shoulder-pain.html>

This document is subject to copyright. Apart from any fair dealing for the purpose of private study or research, no part may be reproduced without the written permission. The content is provided for information purposes only.