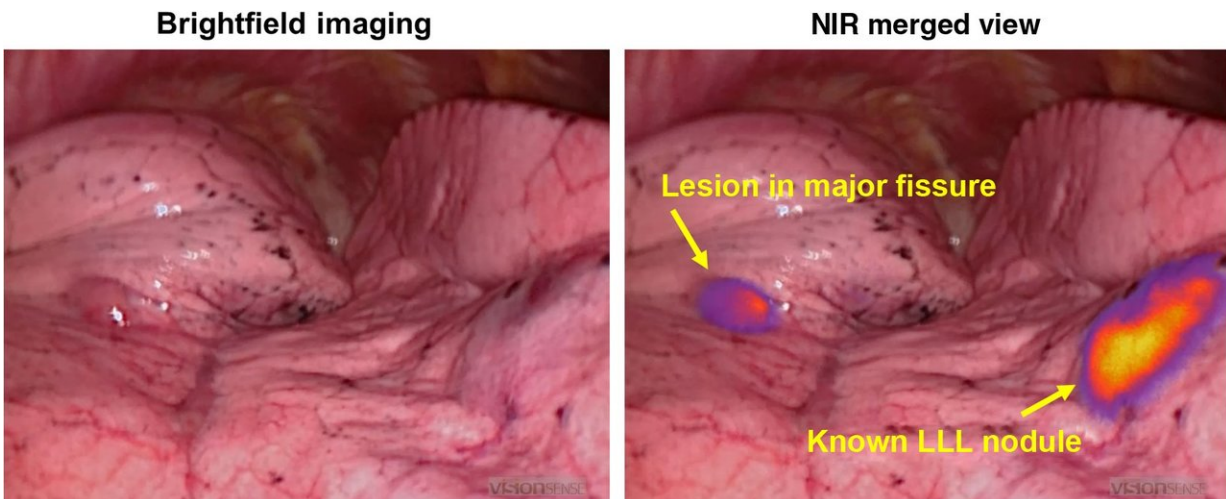


Molecular imaging technique identifies lung nodules for resection in osteosarcoma patient

January 5 2018



Osteosarcoma metastases display in situ fluorescence during intraoperative molecular imaging. Four hours after delivery of OTL38, osteosarcoma metastases display fluorescence during real-time molecular imaging. This technology may help surgeons localize nodules found by preoperative imaging or identify additional small disease deposits which are undetectable using standard imaging/intraoperative modalities. Credit: Jarrod Predina, Andrew Newton, Charuhas Deshpande, and Sunil Singhal of The Perelman School of Medicine at the University of Pennsylvania, and Philip Low of Purdue University

In a proof-of-principle case report, researchers announce that targeted fluorescence successfully identified pulmonary metastases in a patient with osteosarcoma, making it easier for surgeons to locate the tumors for

resection. This advance is reported in an article published today by SPIE, the international society for optics and photonics.

The case study "Utilization of targeted near-infrared molecular imaging to improve pulmonary metastasectomy of osteosarcomas," by Jarrod Predina, Andrew Newton, Charuhas Deshpande, and Sunil Singhal of The Perelman School of Medicine at the University of Pennsylvania, and Philip Low of Purdue University, is notable for its impact on osteosarcoma resection, according to the journal's editor-in-chief, Brian Pogue.

Osteosarcomas express a number of unique molecular markers, including the folate receptor alpha ($FR\alpha$). This study utilized a near-infrared contrast agent known as OTL38, which binds to pulmonary metastases expressing $FR\alpha$, and emits in the NIR range.

In this study, the fluorescence emitted from the contrast agent allowed surgeons to locate both a known lung nodule and a small occult metastases—less than a half a centimeter—that was not visible in preoperative imaging, suggesting that this approach may enable the detection of small or hard-to-locate nodules during minimally invasive resection.

The drug was safely delivered and no toxicity was observed, the authors reported. Both nodules were successfully resected using real-time fluorescence feedback.

The authors report that this technique may enhance the surgeon's ability to perform a variety of oncologic procedures including tumor localization, margin assessment, and intraoperative staging.

"The authors were able to examine the spatial heterogeneity of the folate-dye uptake and show that even though there is a complex uptake pattern,

the shapes were representative of the underlying pathology distribution, and therefore provide a reasonable molecular tag for resection margins," said Brian Pogue.

Initial reports indicate that more than 90% of primary lung cancers accumulate OTL38 and generate tumor [fluorescence](#) during minimally invasive pulmonary resection, suggesting that this technique may have application beyond pulmonary [osteosarcoma](#). Future research will explore if this approach could be applicable to other pulmonary malignancies that express the FR α .

More information: Jarrod D. Predina et al, Utilization of targeted near-infrared molecular imaging to improve pulmonary metastasectomy of osteosarcomas, *Journal of Biomedical Optics* (2018). [DOI: 10.1117/1.JBO.23.1.016005](#)

Provided by SPIE

Citation: Molecular imaging technique identifies lung nodules for resection in osteosarcoma patient (2018, January 5) retrieved 14 August 2024 from <https://medicalxpress.com/news/2018-01-molecular-imaging-technique-lung-nodules.html>

<p>This document is subject to copyright. Apart from any fair dealing for the purpose of private study or research, no part may be reproduced without the written permission. The content is provided for information purposes only.</p>
--