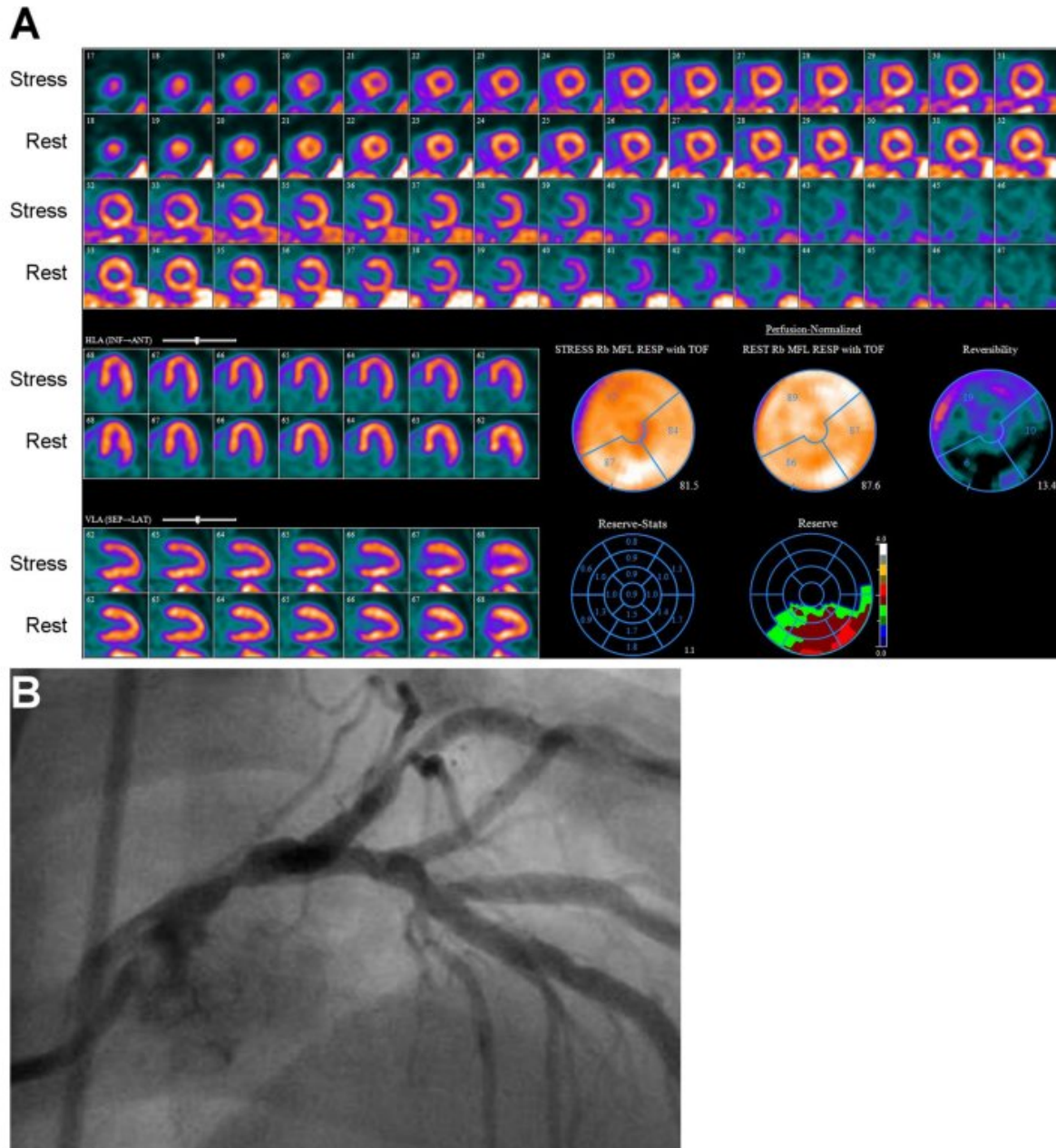


SNMMI and ASNC issue joint guidelines for quantification of myocardial blood flow using PET

February 13 2018



In this example, from an 81-year-old man with hypertension and dyslipidemia, relative MPI (A) with 82Rb PET demonstrated only mild, reversible perfusion abnormality involving distribution of left anterior descending coronary artery. However, MFR was severely reduced globally at 1.11. Nearly entire heart had severely reduced MFR except for inferior and inferolateral walls, where it was only moderately reduced. Coronary angiography (B) showed severe stenosis of mid portion of left main coronary artery. Credit: American Society of Nuclear

The Society of Nuclear Medicine and Molecular Imaging's (SNMMI) Cardiovascular Council and the American Society of Nuclear Cardiology (ASNC) have issued the joint position paper, Clinical Quantification of Myocardial Blood Flow Using PET, which was jointly published in the *Journal of Nuclear Cardiology* and *The Journal of Nuclear Medicine*.

Radionuclide [myocardial perfusion imaging](#) (MPI) is among the most commonly performed diagnostic tests in cardiology. Positron emission tomography (PET) can quantify global and regional myocardial [blood flow](#), assess regional perfusion abnormalities with relative MPI, and assess function abnormalities and chamber dimensions. Quantification of myocardial blood flow requires accurate measurement of the total tracer activity transported by the arterial blood and delivered to the myocardium over time.

This position statement consolidates and updates technical considerations for clinical quantification of myocardial blood flow and myocardial flow reserve, and it summarizes and updates the scientific basis for their clinical application.

"Quantification of myocardial blood flow is the next great leap in nuclear [cardiology](#), and this document summarizes the data supporting its use and offers guidance to those who are planning to make these measurements in practice," explains Venkatesh L. Murthy, MD, PhD, vice president-elect of SNMMI's Cardiovascular Council and a lead author of the position statement.

Prem Soman, MD, PhD, FACC, FASNC, president of ASNC and co-author of the document, points out, "This is a comprehensive document

which offers many useful insights into the theory and practice of PET myocardial perfusion imaging."

The position paper states, "Quantification of myocardial blood flow and myocardial flow reserve represents a substantial advance for diagnostic and prognostic evaluation of suspected or established coronary artery disease. These methods are at the cusp of translation to clinical practice." It notes, however, that further efforts are necessary to standardize measures across laboratories, radiotracers, equipment, and software—pointing out, "Most critically, data are needed supporting improved clinical outcomes when treatment selection is based on these measures."

More information: Venkatesh L. Murthy et al, Clinical Quantification of Myocardial Blood Flow Using PET: Joint Position Paper of the SNMMI Cardiovascular Council and the ASNC, *Journal of Nuclear Medicine* (2017). [DOI: 10.2967/jnumed.117.201368](https://doi.org/10.2967/jnumed.117.201368)

Provided by Society of Nuclear Medicine and Molecular Imaging

Citation: SNMMI and ASNC issue joint guidelines for quantification of myocardial blood flow using PET (2018, February 13) retrieved 10 April 2024 from <https://medicalxpress.com/news/2018-02-snmml-asnc-issue-joint-guidelines.html>

| |
|--|
| <p>This document is subject to copyright. Apart from any fair dealing for the purpose of private study or research, no part may be reproduced without the written permission. The content is provided for information purposes only.</p> |
|--|