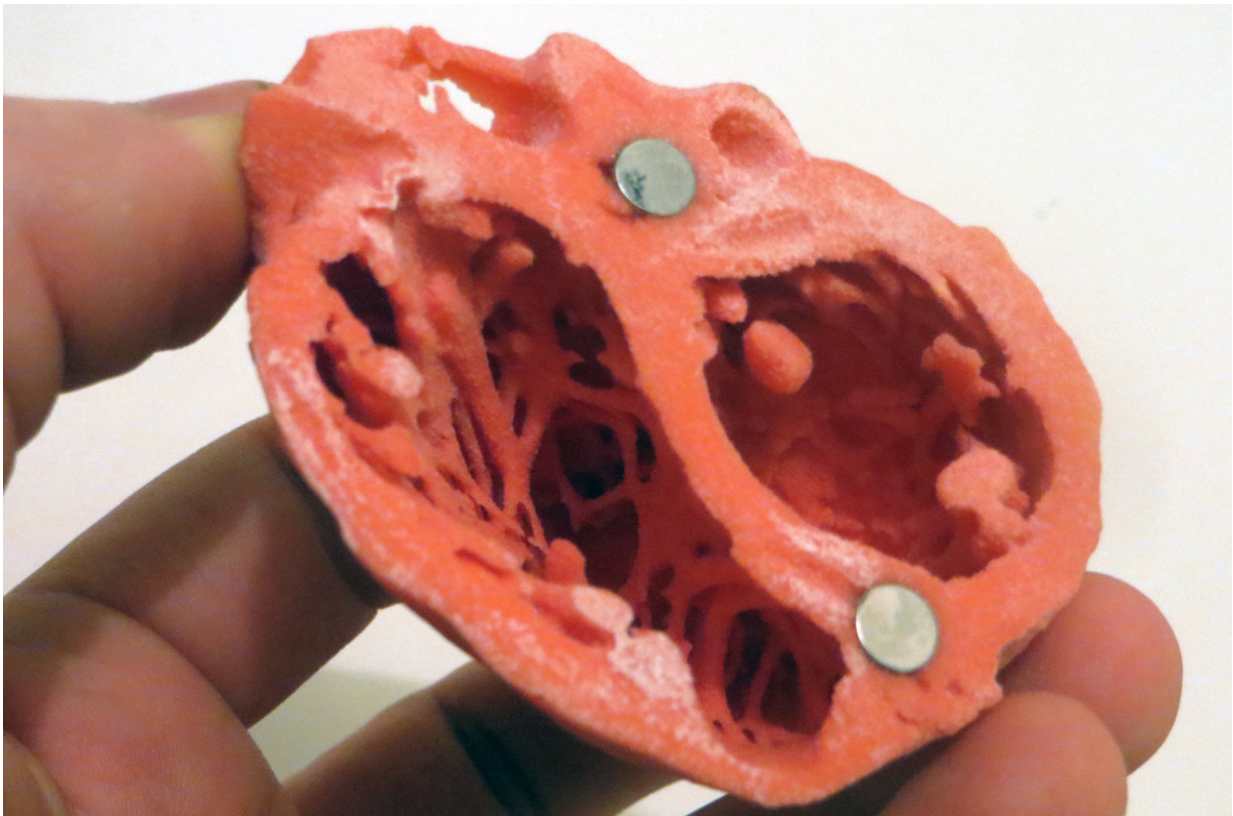


Patient-friendly and accurate cardiac damage diagnosis

September 7 2018



3D Model of the heart by Dr. Matthew Bramlet. Credit: NIH

Systemic inflammatory diseases, such as lupus, often cause cardiac damage that goes undetected. An international research team headed by the Institute for Experimental and Translational Cardiovascular Imaging

at the University Hospital Frankfurt was now able to show via heart imaging that cardiac damage can be diagnosed in a patient-friendly way ahead of the clinical symptoms.

The number of diagnoses of systemic lupus erythematoses (SLE) has tripled over the past 45 years, due in part to improved diagnostic methods. Lupus is a systemic inflammatory disease that can affect several organs, most frequently, the kidneys, skin, brain and the heart. Involvement of the heart is important, as it determines the outcome, yet can remain undetected and untreated for a long time.

This problematic situation has several causes. First, the natural course of lupus-caused heart disease often has few or no symptoms—this subclinical course represents a major challenge for diagnosis. It also predominantly affects young female patients, for whom heart disease is unusual in the first place. Moreover, if symptoms occur, they are not classical symptoms of heart disease, such as angina. More commonly, symptoms are atypical—in other words, they do not explicitly indicate [heart disease](#). Examples of symptoms are tiredness, dyspnoea, or sharp pain of the chest wall. Lupus patients are also frequently overwhelmed by symptoms in other organ systems, especially the kidneys, which are significantly more pronounced. As a result, clinicians may mistakenly focus on these organs instead of the heart during diagnosis and treatment. Ultimately, a small percentage of patients develops heart failure, which is often resistant to therapy.

A study by the University Hospital Frankfurt in collaboration with partners from London and Tübingen has shown that imaging with [cardiac magnetic resonance](#) (CMR) can improve detection of subclinical cardiac injury in [lupus patients](#). The study was published in the *Annals of the Rheumatic Diseases*. In the present study, the authors demonstrated that inflammation of [heart muscle](#) and the vessels is the defining underlying pathophysiological mechanism of heart injury and

impairment in lupus patients, and not, as previously assumed, as a result of the accelerated atherosclerotic blockage of the coronary blood vessels. The research team developed and validated an imaging signature of disease presence and activity of involvement. Thus, they have shown that heart inflammation can be detected and monitored in a noninvasive way without radiation using CMR imaging. Furthermore, CMR imaging can help clinicians to adjust the anti-inflammatory treatment to treat the heart involvement directly.

The study has significant potential for a real change in the clinical care of heart involvement in patients with lupus, replacing the current less sensitive, highly invasive and radiation-intensive methods with patient-friendly and secure diagnostic approaches that are noninvasive, radiation-free, and aside from the baseline investigation, also largely free from contrast agents. The new diagnostic method accurately assesses disease presence, stage and severity, and gauges the treatment response.

Ninety-two patients with lupus were examined using the CMR imaging; 78 healthy individuals served as a control group. This multicentre and multidisciplinary study was headed by Dr. Valentina Puntmann from the Institute for Experimental and Translational Cardiovascular Imagery (Goethe CVI) at the University Hospital Frankfurt and builds on a decade-long record of investigation into cardiac inflammation by noninvasive imaging in systemic inflammatory diseases. In addition to the Goethe CVI, University Hospital Frankfurt's Rheumatology, Cardiology and Radiology were also involved.

The heart muscle, its volume, and function were examined in all participants using CMR imaging. Various other blood values, such as troponin and NT-proBNP, which serve as biomarkers for heart impairment, were also examined. These markers were raised in 81 percent of lupus patients, but only in eight percent to a degree we usually see in the course of a heart attack. However, CMR imaging was able to

point towards the presence of relevant inflammation of [heart](#) muscle much more frequently, making it more suited to detect inflammation, even if the blood tests remain only mildly raised. In addition, changes to the clinical activity can be more quickly detected using the imaging than with blood values, as these may remain raised for weeks on end. There are no disadvantages to CMR, as no invasive procedures or radiation are involved.

More information: Lea Winau et al, High-sensitive troponin is associated with subclinical imaging biosignature of inflammatory cardiovascular involvement in systemic lupus erythematosus, *Annals of the Rheumatic Diseases* (2018). [DOI: 10.1136/annrheumdis-2018-213661](#)

Provided by Goethe University Frankfurt am Main

Citation: Patient-friendly and accurate cardiac damage diagnosis (2018, September 7) retrieved 2 May 2024 from <https://medicalxpress.com/news/2018-09-patient-friendly-accurate-cardiac-diagnosis.html>

<p>This document is subject to copyright. Apart from any fair dealing for the purpose of private study or research, no part may be reproduced without the written permission. The content is provided for information purposes only.</p>
--