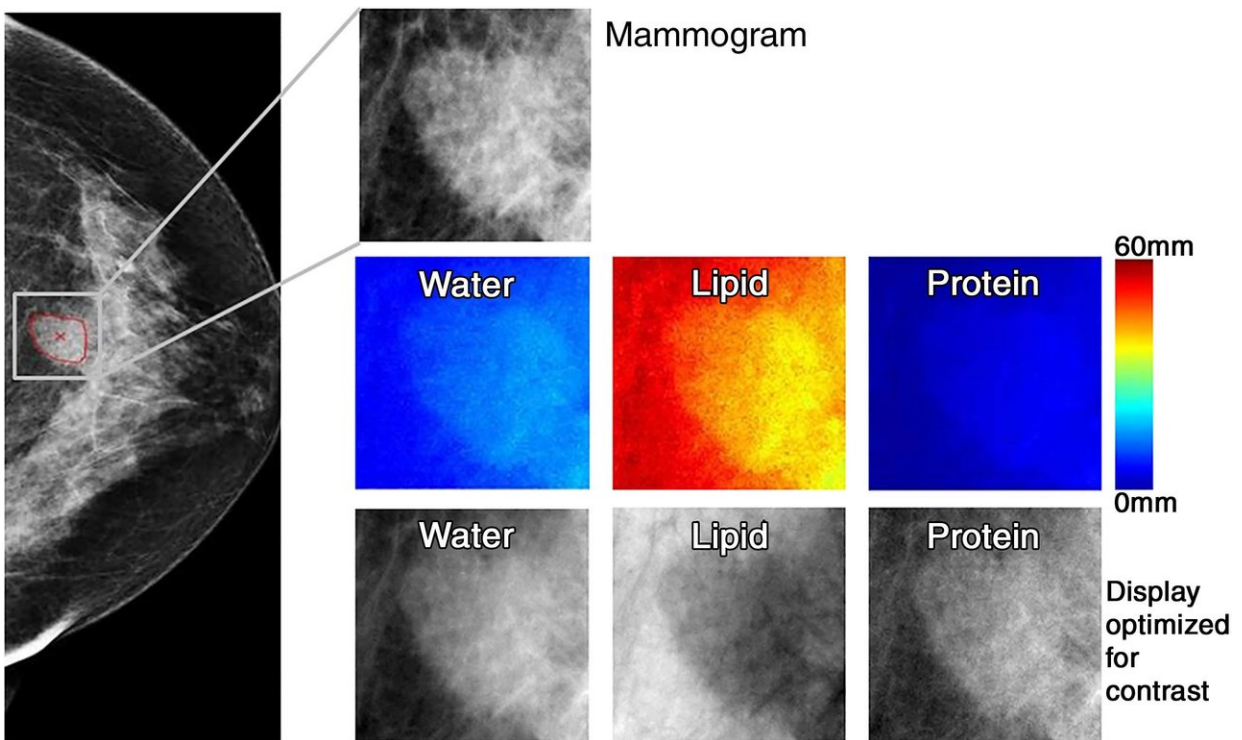


Novel technique may significantly reduce breast biopsies

December 11 2018



Images in 71-year-old woman with 1.6-cm invasive ductal carcinoma (Breast Imaging Reporting and Data System category 5, with category C breast density). Low-energy mammo-gram and corresponding regions of interest for mammogram (top) and breast tissue composi-tion images (bottom two rows). Credit: Radiological Society of North America

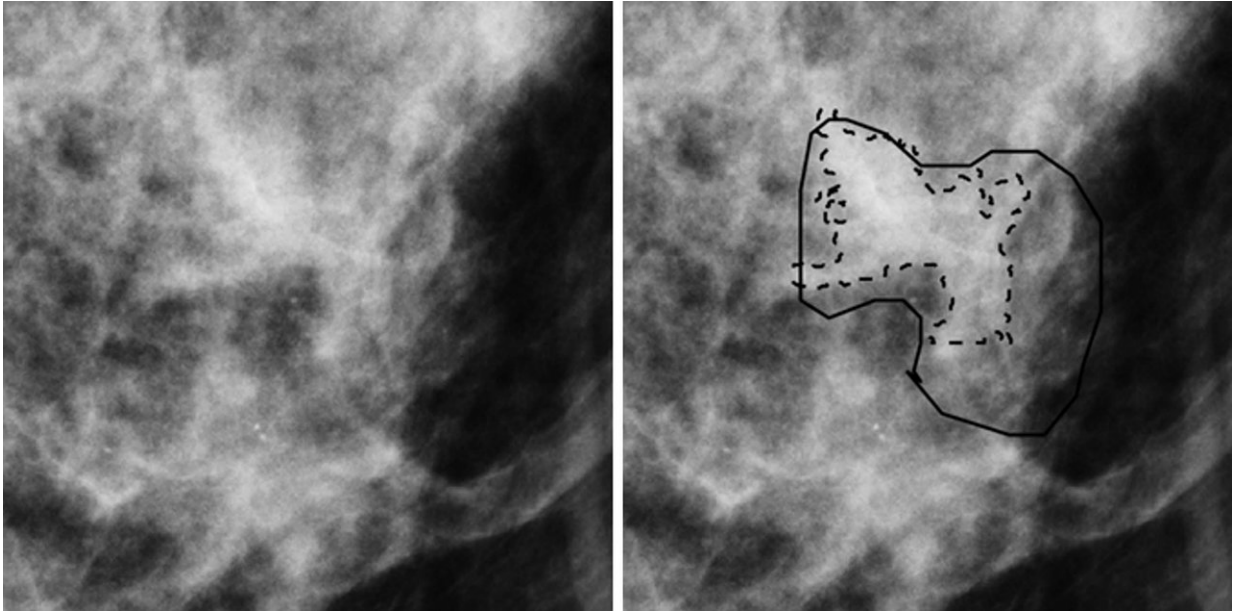
A novel technique that uses mammography to determine the biological

tissue composition of a tumor could help reduce unnecessary breast biopsies, according to a new study appearing in the journal *Radiology*.

Mammography has been effective at reducing deaths from [breast](#) cancer by detecting cancers in their earliest, most treatable stages. However, many women are called back for additional diagnostic imaging and, in many cases, biopsies, for abnormal findings that are ultimately proven benign. Research estimates this recall rate to be more than 10 percent in the United States.

"The callback rate with [mammography](#) is much higher than ideal," said the study's first author, Karen Drukker, Ph.D., research associate professor from the Department of Radiology at the University of Chicago in Chicago. "There are costs and anxiety associated with recalls, and our goal is to reduce these costs but not miss anything that should be biopsied."

Dr. Drukker and colleagues recently studied a new technique called three-compartment breast (3CB) imaging. John Shepherd, Ph.D., currently at the University of Hawaii in Honolulu, and his team developed 3CB while he was at the University of California in San Francisco. By measuring the water, lipid and protein tissue composition throughout the breast, 3CB might provide a biological signature for a tumor. For instance, more water in the tumor tissue might indicate angiogenesis, or the production of new blood vessels, an early sign of cancer development.



Region of interest from digital mammography depicts invasive cancer misclassified with mammography radiomics. Images in 50-year-old woman with invasive cancer (Breast Imaging Reporting and Data System category 4, with category C breast density) without (left) and with (right) radiologist and computer delineations (solid and dashed lines, respectively). Credit: Radiological Society of North America

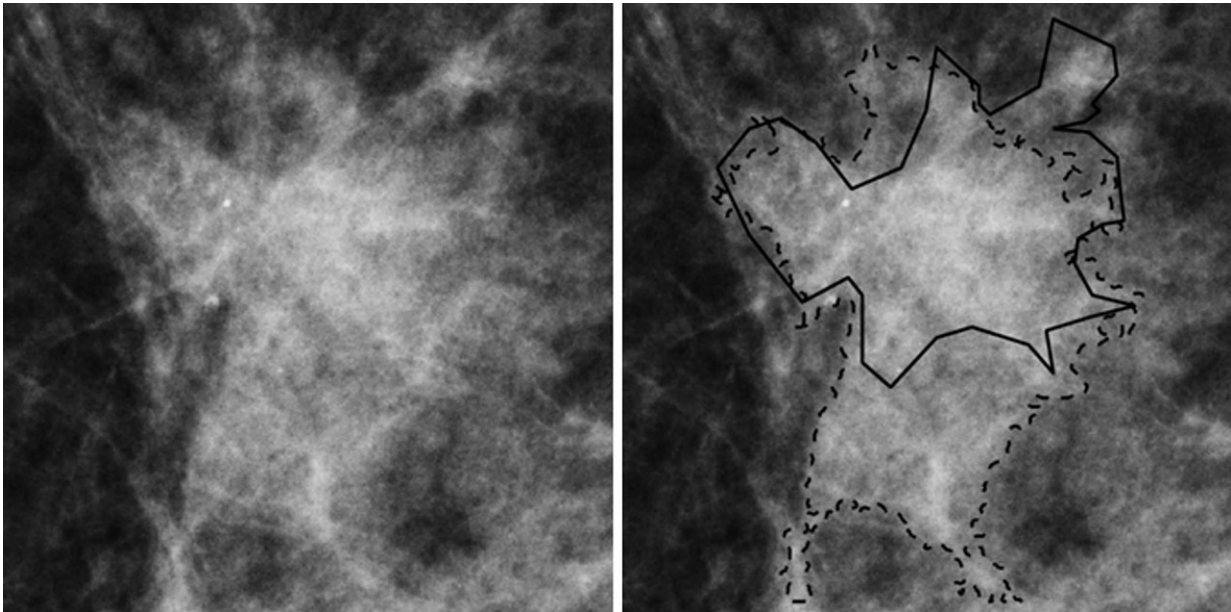
For the study, the researchers acquired dual-energy mammograms from 109 women with breast masses that were suspicious or highly suggestive of a malignancy—the types of lesions that typically would be biopsied—immediately prior to biopsy, and the ensuing biopsies showed 35 masses to be invasive cancers, while the remaining 74 were benign.

3CB images were derived from the dual-energy mammograms and analyzed along with mammography radiomics, a method that uses artificial intelligence algorithms to analyze features and patterns in images—some of which are difficult for [human perception](#)—developed by Maryellen L. Giger, Ph.D., and her team at the University of Chicago

for use in computer-aided diagnosis on breast images.

The combination of 3CB image analysis and radiomics improved the [positive predictive value](#), or the ability to predict [cancer](#), in breast masses deemed suspicious by the breast radiologist. The combined method improved positive predictive value from 32 percent for visual interpretation alone to almost 50 percent, with an almost 36 percent reduction in biopsies. The 3CB-radiomics method missed one of the 35 cancers, for a 97 percent sensitivity rate.

"These results are very promising," Dr. Drukker said. "Combining 3CB image analysis with mammography radiomics, the reduction in recalls was substantial."



Region of interest from digital mammography depicts invasive cancer misclassified with quantitative three-compartment breast (3CB) analysis and combined mammography radiomics plus quantitative 3CB analysis. Images in 53-year-old woman with invasive cancer (Breast Imaging Reporting and Data System category 4, with category C breast density) without (left) and with (right)

radiologist and computer delineations (solid and dashed lines, respectively).
Credit: Radiological Society of North America

Dr. Drukker said the combined 3CB-radiomics approach has the potential to play an increasingly prominent role in [breast cancer](#) diagnosis and perhaps also screening. She noted that 3CB can easily be added to mammography without requiring extensive modifications of existing equipment.

"The patient is already getting the mammography, plus we get all this extra information with only a 10 percent additional dose of radiation," she said.

This approach is still experimental at this stage, and further work is needed to make it available to patients. The researchers plan to study how the combined approach will help radiologists make their final determinations. They also want to study the approach using digital breast tomosynthesis, sometimes called "3-D" mammography, which reduces the problem of overlapping breast tissue inherent to regular mammography. A tumor's unique water-lipid-protein signature might be even clearer with tomosynthesis, Dr. Drukker said.

More information: "Combined Benefit of Quantitative Three-Compartment Breast Image Analysis and Mammography Radiomics in the Classification of Breast Masses in a Clinical Data Set." *Radiology*, 2018.

Provided by Radiological Society of North America

Citation: Novel technique may significantly reduce breast biopsies (2018, December 11)
retrieved 24 April 2024 from
<https://medicalxpress.com/news/2018-12-technique-significantly-breast-biopsies.html>

This document is subject to copyright. Apart from any fair dealing for the purpose of private study or research, no part may be reproduced without the written permission. The content is provided for information purposes only.