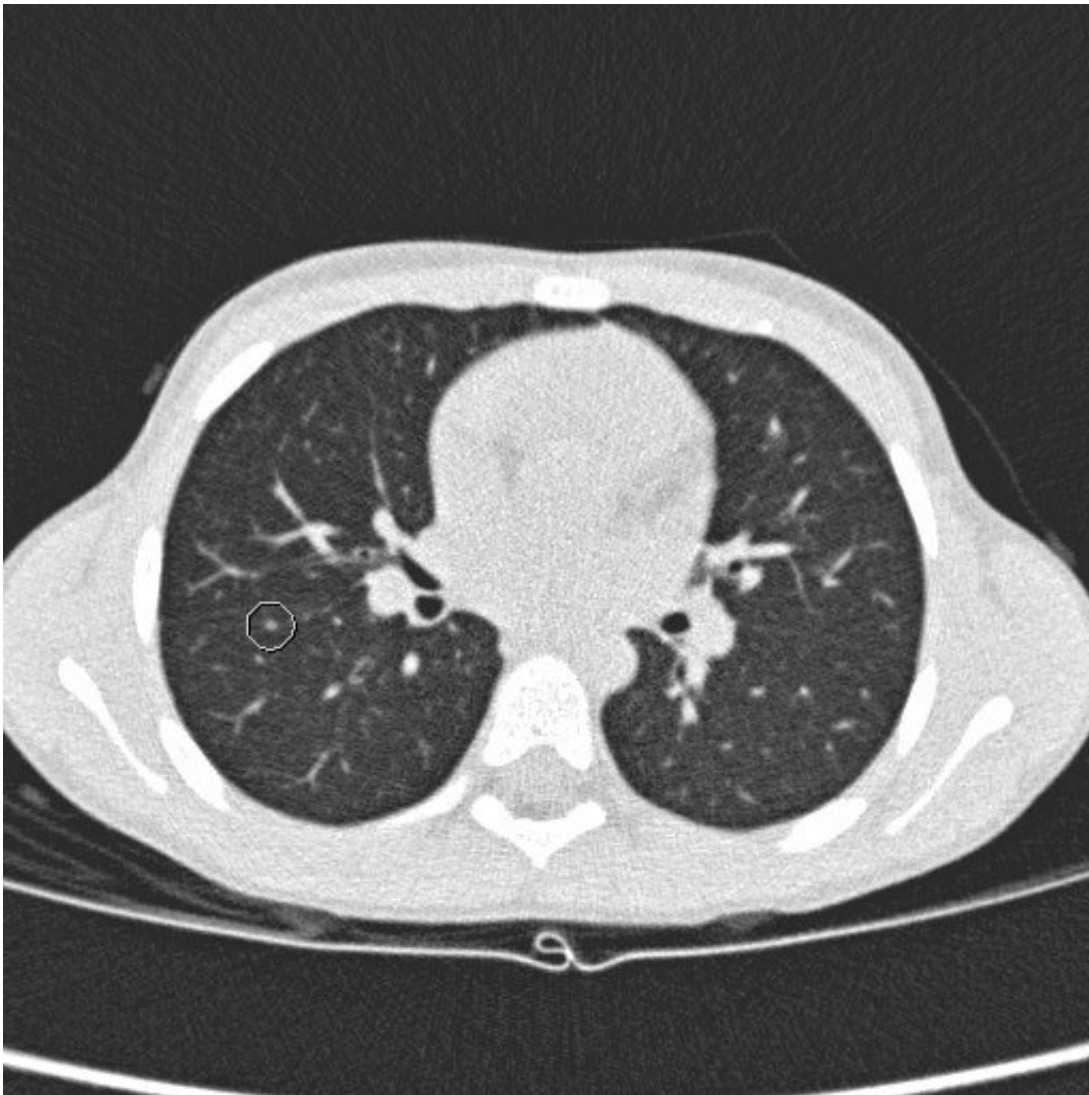


Suspicious spots on the lungs do not behave like metastases of rhabdomyosarcoma

February 15 2019



Small pulmonary nodules in children with rhabdomyosarcoma do not behave like metastases. Credit: Princess Máxima Center for Pediatric Oncology

Small spots on CT scans of the lungs of children with muscle cancer do not have an adverse effect on survival, according to an international research team in the *Journal for Clinical Oncology*. This conclusion has direct consequences for the treatment of the disease.

Rhabdomyosarcoma is a malignant soft tissue tumor in the muscle tissue of [children](#) and adolescents. About 20 children are diagnosed with rhabdomyosarcoma per year in the Netherlands. "Metastases in these children are often found in the lungs," says professor Hans Merks of the Princess Máxima Center for Pediatric Oncology, who led the study. "We can detect those metastases on CT scans of the lungs. In addition to the easily recognizable metastases, these CT scans regularly show small spots on the lungs. We did not know if these were metastases until now."

To find out what these small spots mean, the team re-examined all CT scans in a large European study of more than 300 children with rhabdomyosarcoma. About 1 in 5 children had these small spots on the lungs. The future prospects of the children with small spots turned out to be just as good as those of children without abnormalities on their [lung](#) CT.

"This is good news," says Merks. "It means that these children do not need to be treated with extra strong medicines that are potentially harmful to the heart; they also do not need to be treated for longer or need radiation on their lungs, as is the case when children have larger lung [metastases](#)."

Since the chances of survival are high for children with [rhabdomyosarcoma](#), this is important news. A more aggressive treatment often causes problems later in life. This study shows that a more aggressive treatment is not necessary when small spots are visible on the CT scans. This increases the chance of a good quality of life without limitations for ex-patients.

More information: Bas Vaarwerk et al, Indeterminate Pulmonary Nodules at Diagnosis in Rhabdomyosarcoma: Are They Clinically Significant? A Report From the European Paediatric Soft Tissue Sarcoma Study Group, *Journal of Clinical Oncology* (2019). [DOI: 10.1200/JCO.18.01535](https://doi.org/10.1200/JCO.18.01535)

Provided by Princess Máxima Center for Pediatric Oncology

Citation: Suspicious spots on the lungs do not behave like metastases of rhabdomyosarcoma (2019, February 15) retrieved 19 April 2024 from <https://medicalxpress.com/news/2019-02-suspicious-lungs-metastases-rhabdomyosarcoma.html>

This document is subject to copyright. Apart from any fair dealing for the purpose of private study or research, no part may be reproduced without the written permission. The content is provided for information purposes only.