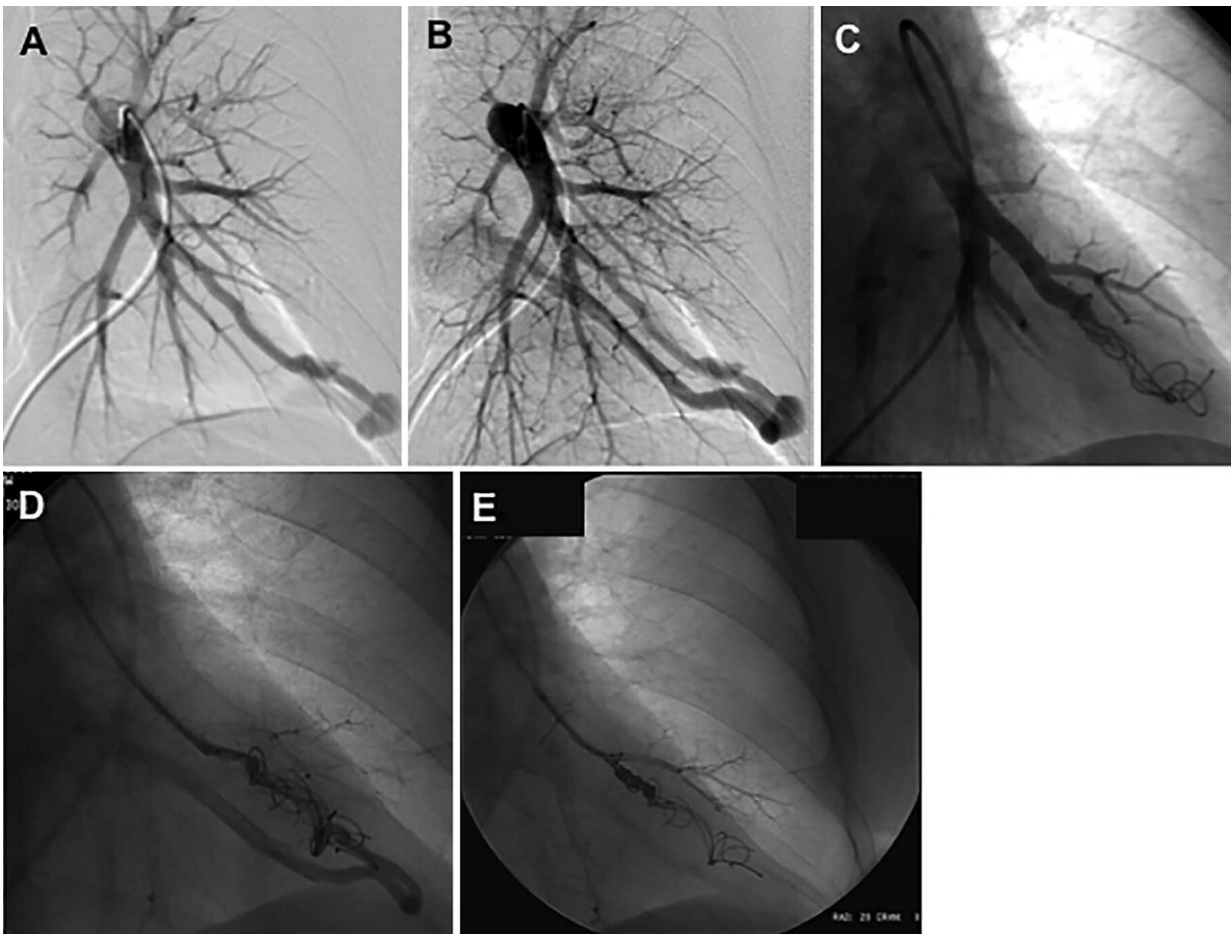


Smoking impedes embolization treatment in lungs

July 30 2019



Images in a 52-year-old woman with hereditary hemorrhagic telangiectasia demonstrating on left pulmonary artery angiogram an arteriovenous malformation (AVM) at, A, B, the left base. C, Selective angiogram after embolization of the AVM by using coils. D, E, Angiogram shows embolization for persistence treated with repeat embolization performed 2 years after initial embolization. Credit: Radiological Society of North America

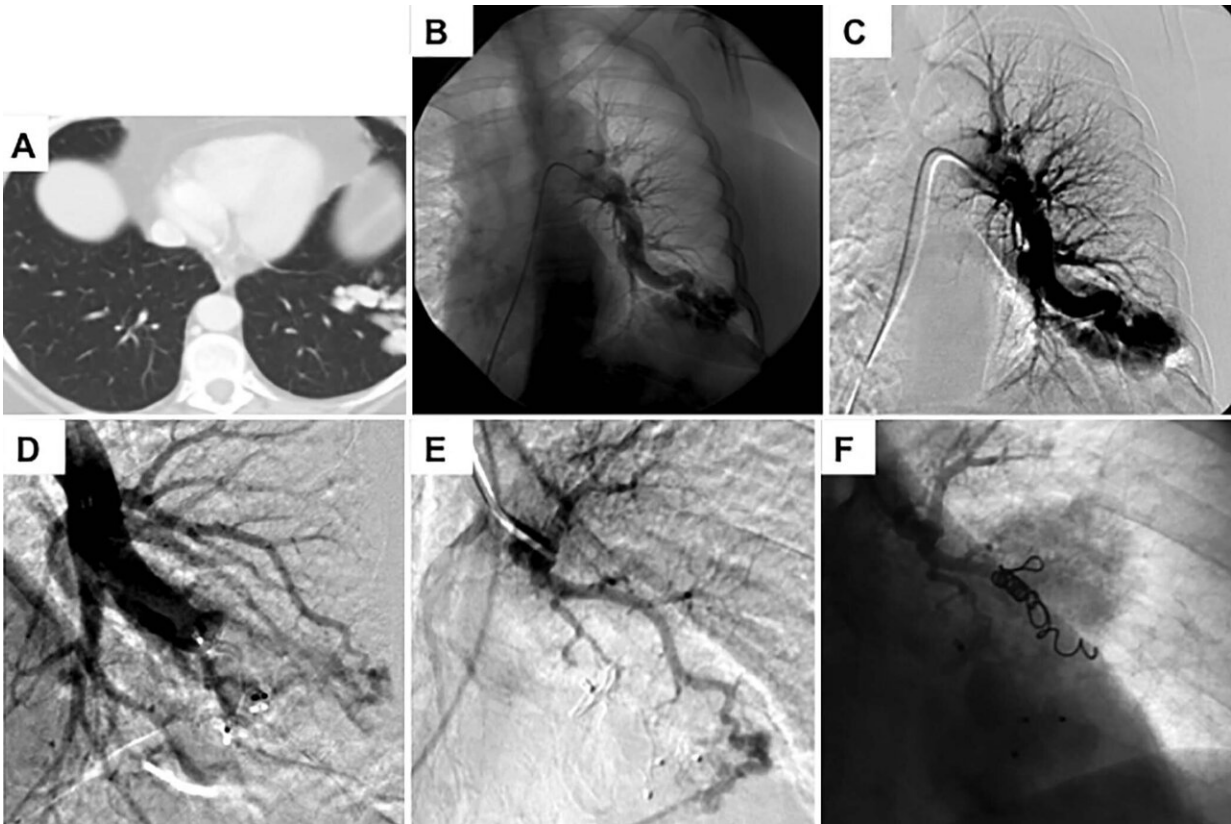
Smoking reduces the chances of a successful procedure to treat blood vessel abnormalities in the lungs, according to a study published in the journal *Radiology*.

Pulmonary arteriovenous malformations (PAVMs) are abnormal connections between arteries and veins in the lungs. The abnormalities can become symptomatic and lead to potentially dangerous complications. PAVMs are strongly associated with an inherited disorder called Hereditary Hemorrhagic Telangiectasia (HHT).

"HHT is a disease that can manifest with patients having AVMs in their lungs," said study senior author Sanjay Misra, M.D., an interventional radiologist at the Mayo Clinic Department of Radiology in Rochester, Minn. "When these AVMs become symptomatic, we are asked to embolize them using coils."

In the embolization procedure, a catheter is threaded from a large blood vessel in the leg to the site of the PAVM. A small coil is then inserted to block the PAVM. The procedure is highly effective, but the PAVMs will persist in some patients.

For the new study, Dr. Misra and colleagues wanted to see how [smoking](#) might affect post-embolization PAVM persistence rates. They looked at 103 patients with HHT who underwent embolization for a total of 373 PAVMs. The patients were classified into smoking or non-smoking groups.



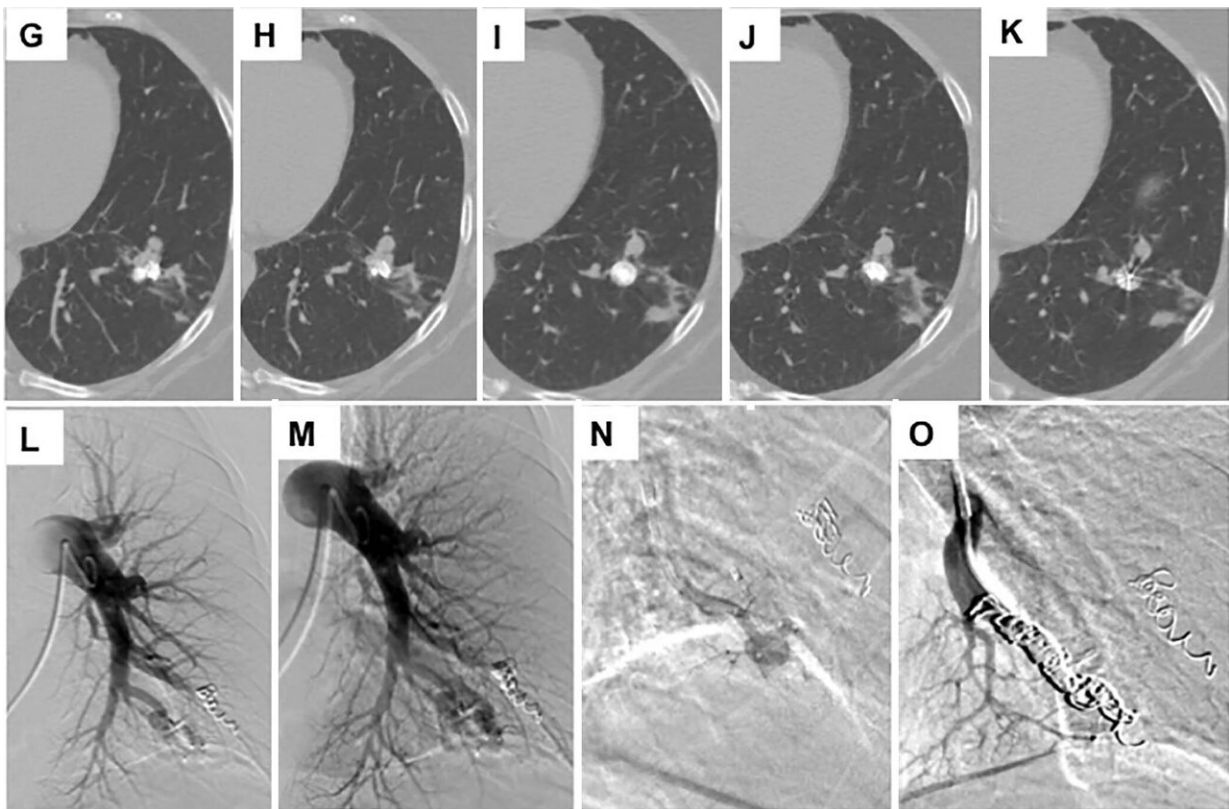
Images in a 68-year-old woman with hereditary hemorrhagic telangiectasia (HHT) and a smoking history of 40 pack-years demonstrating, A, a complex arteriovenous malformation (AVM) at the left base on intravenous contrast-enhanced chest CT scan. B, C, Left pulmonary artery angiogram shows the AVM. D, Image after embolization and after placement of an Amplatzer plug. E, A selective angiogram of the second arterial blood supply to the AVM. F, Angiogram after coil embolization. Credit: Radiological Society of North America

Smokers faced a higher rate of PAVM persistence following treatment than those who had never smoked. Patients reporting active tobacco use at the time of PAVM embolization had a five-year persistence rate of 26.3 percent compared with 13.5 percent in inactive [smokers](#).

PAVMs persisted after treatment in more than a third of smokers with more than 20 pack-years, compared with only 12.2 percent of nonsmokers. Pack years is a measure of smoking intensity that accounts for how long and how much a person has smoked.

"Our five-year data showed that the cumulative incidence of persistence was 17.3 percent, or almost one in five patients," Dr. Misra said.

"Smoking more than 20 pack years was associated with a fivefold increase in PAVM recurrence."



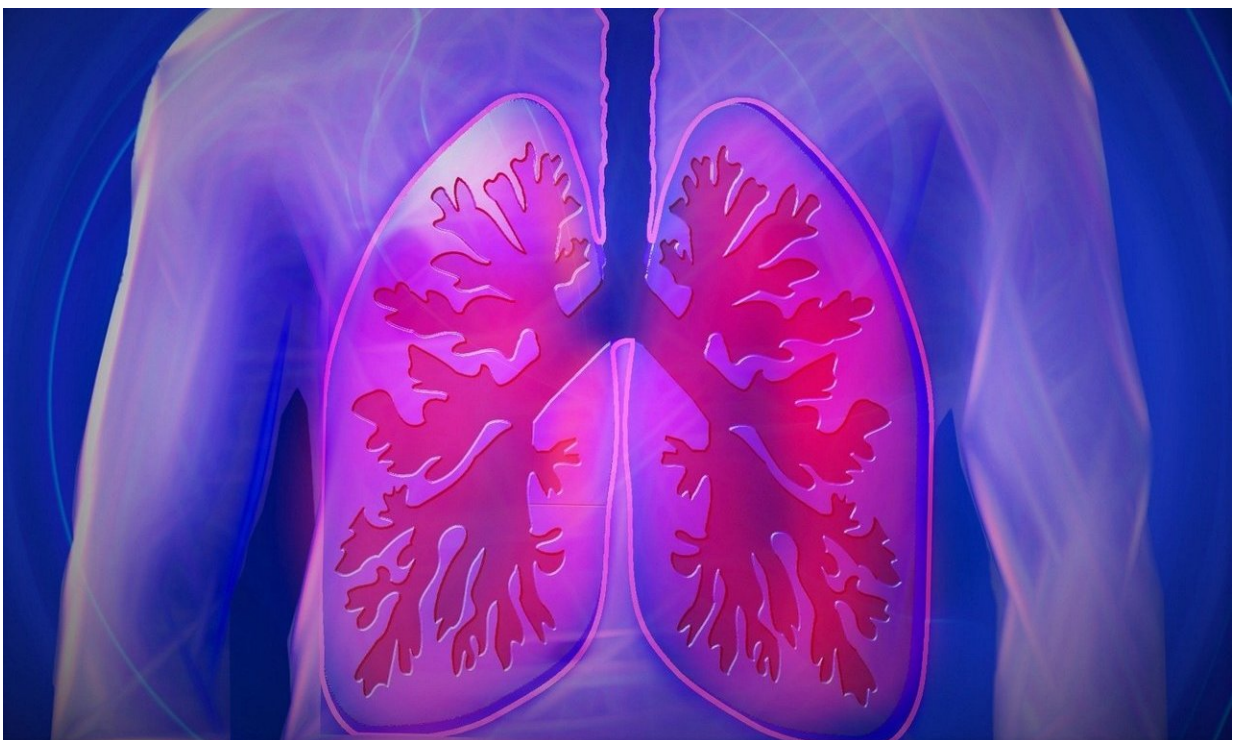G-K, Selective 1.5-mm intravenous contrast-enhanced axial CT images show persistence of the AVM 1 year later. L-M, Left pulmonary artery angiogram shows persistence. N, Selective catheterization of the artery supplying the AVM. O, Angiogram after embolization of the AVM after coil embolization. Credit: Radiological Society of North America

While the study did not assess the reason for the post-embolization persistence of PAVMs in smokers, previous research has linked smoking with inflammation and abnormalities in the formation of new blood vessels.

"Smoking creates an inflammatory response," Dr. Misra said. "More inflammation creates a greater likelihood of failure for smokers compared to those who never smoked."

The findings, if confirmed in larger studies, could be used to advise patients with HHT who might be considering embolization for PAVMs.

"Smoking cessation is very important if these patients want to help themselves and avoid further procedures," Dr. Misra said. "We should urge current smokers to stop smoking before treatment."



Credit: CC0 Public Domain

More information: Smoking Significantly Impacts Persistence Rates in Embolized Pulmonary Arteriovenous Malformations in Patients with Hereditary Hemorrhagic Telangiectasia, *Radiology*, 2019.

Provided by Radiological Society of North America

Citation: Smoking impedes embolization treatment in lungs (2019, July 30) retrieved 7 May 2024 from <https://medicalxpress.com/news/2019-07-impedes-embolization-treatment-lungs.html>

<p>This document is subject to copyright. Apart from any fair dealing for the purpose of private study or research, no part may be reproduced without the written permission. The content is provided for information purposes only.</p>
--