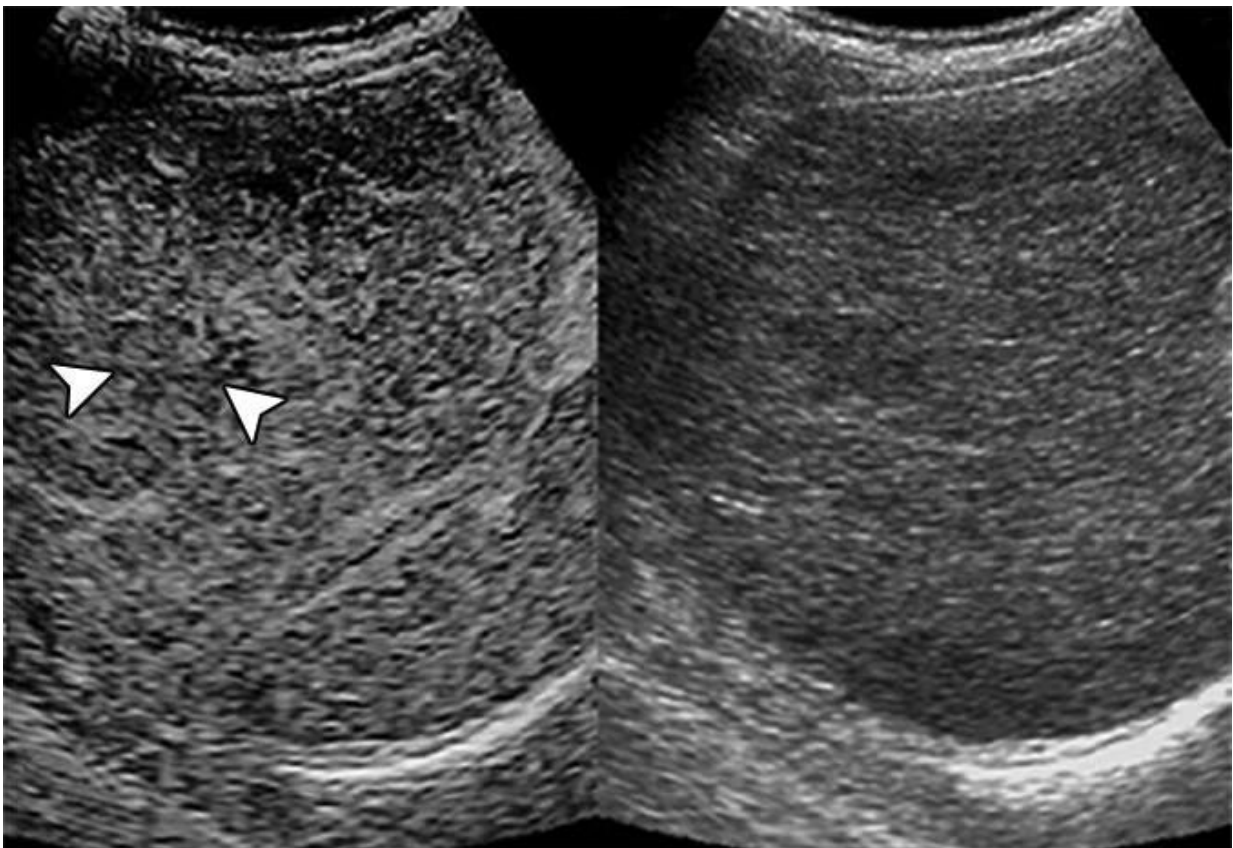


Contrast-enhanced ultrasound predicts nodule transformation to hepatocellular carcinoma

October 24 2019



At initial detection, contrast arrival time difference between nodule and liver was 1.87 seconds. Contrast-enhanced (left) and conventional (right) ultrasound images. At 30.07 seconds, nodule (arrowheads, left image) is isoenhanced compared with surrounding liver. Credit: *American Journal of Roentgenology (AJR)*

An article published ahead-of-print in the January 2020 issue of the *American Journal of Roentgenology* (AJR) has identified sonographic biomarkers that can predict eventual malignant transformation of pathologically confirmed cirrhotic nodules for patients at risk for hepatocellular carcinoma (HCC).

Lead investigator Manxia Lin of China's Sun Yat-Sen University retrospectively studied 39 consecutive patients with 44 pathologically confirmed cirrhotic [nodules](#) who initially underwent contrast-enhanced ultrasound (CEUS) examination at detection, followed by conventional ultrasound every 3-4 months thereafter.

Fourteen nodules (31.8%) evidenced eventual malignant transformation after a median follow-up time of 26.7 months.

According to Lin and colleagues' results, the contrast arrival time difference between the cirrhotic nodule and the liver on CEUS proved useful in stratifying eventual malignant transformation risk—"which may enable a more customized surveillance strategy," they noted.

"During surveillance," Lin *et al.* continued, "a [relative growth rate](#) of 30% or greater in 6 months or an absolute growth rate of 5 mm or greater in 6 months highly indicated malignant transformation."

Moreover, Lin's team determined that the absence of both echogenicity change and threshold growth "significantly excluded malignant [transformation](#)."

Acknowledging that additional studies will be necessary for validating possible biomarkers, Lin concluded: "These additional imaging features may have the potential to be adopted as ancillary or even major features to stratify probability for HCC in the CEUS LI-RADS system."

More information: Manxia Lin et al, Cirrhotic Nodule Transformation to Hepatocellular Carcinoma: Natural History and Predictive Biomarkers on Contrast-Enhanced Ultrasound, *American Journal of Roentgenology* (2019). [DOI: 10.2214/AJR.19.21739](https://doi.org/10.2214/AJR.19.21739)

Provided by American Roentgen Ray Society

Citation: Contrast-enhanced ultrasound predicts nodule transformation to hepatocellular carcinoma (2019, October 24) retrieved 9 April 2024 from <https://medicalxpress.com/news/2019-10-contrast-enhanced-ultrasound-nodule-hepatocellular-carcinoma.html>

<p>This document is subject to copyright. Apart from any fair dealing for the purpose of private study or research, no part may be reproduced without the written permission. The content is provided for information purposes only.</p>
--