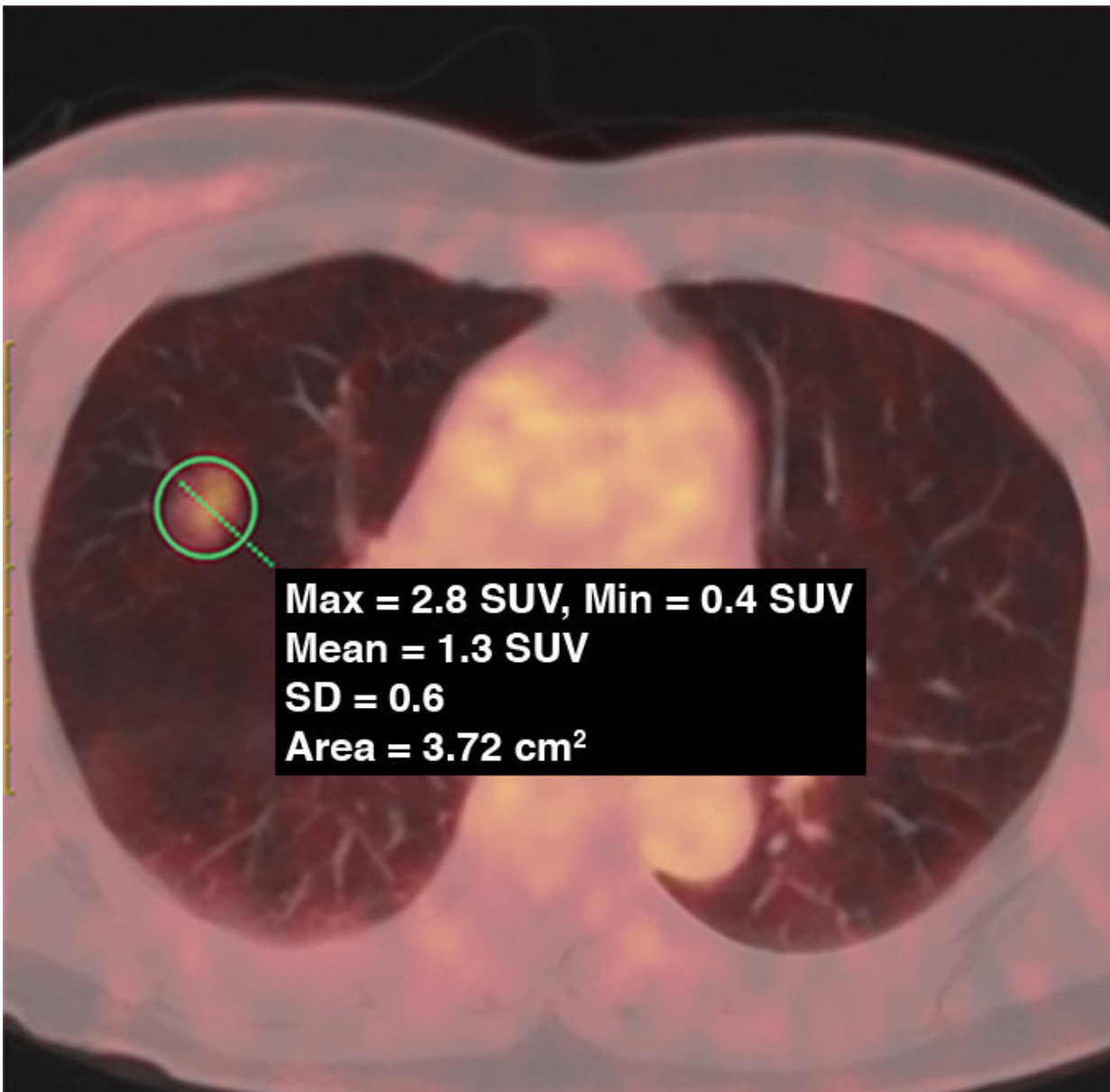


# PET/CT plays role in lung adenocarcinoma management

December 16 2019

---



62-year-old woman with pure GGN. PET/CT fusion image shows pure GGN with tumor maximum standardized uptake value (SUVmax) of 2.8 (circle).  
Credit: *American Journal of Roentgenology* (AJR)

According to an article published ahead-of-print in the February 2020 issue of the *American Journal of Roentgenology* (AJR), fluorodeoxyglucose PET (FDG PET) can be used to predict the histopathologic subtypes and growth patterns of early lung adenocarcinoma.

"FDG PET, combined with high-resolution CT (HRCT), has value for predicting invasive histopathologic subtypes, but there was no significance for predicting invasive growth patterns," clarified lead author Xiaoliang Shao from the department of nuclear medicine at Soochow University in Changzhou, China.

Shao and colleagues' retrospective analysis was conducted on the PET/CT data on ground-glass nodules (GGNs) resected from patients with stage IA [lung adenocarcinoma](#), evaluating the efficacy of PET maximum standardized uptake value (SUVmax) combined with HRCT signs in prediction of histopathologic subtype and growth pattern of lung adenocarcinoma.

Although SUVmax measured significantly higher in GGNs with invasive HRCT signs, the diameter of GGN, as well as the attenuation value differential between ground-glass components and adjacent lung tissues, were independent predictors of FDG uptake by GGNs.

Additionally, SUVmax was higher in invasive adenocarcinoma than in adenocarcinoma in situ (AIS)-minimally invasive adenocarcinoma (MIA), with SUVmax 2.0 the optimal cutoff value for differentiation.

Acinar-papillary adenocarcinoma had a higher SUVmax than lepidic adenocarcinoma, with SUVmax 1.4 the optimal cutoff value for differentiation.

"In stage IA lung adenocarcinoma characterized by GGNs, the SUVmax of GGNs with invasive CT features was high," Shao wrote, adding that HRCT can be used in diagnosing the subtypes of lung adenocarcinoma.

"However, it cannot be used to differentiate different growth patterns of lung adenocarcinomas."

As Shao concluded: "The efficacy of FDG PET SUVmax in differentiating lung adenocarcinoma subtypes is similar to that of HRCT signs, however, the diagnostic efficiency of FDG PET combined with HRCT is significantly higher than that of each imaging technique alone."

**More information:** Xiaoliang Shao et al, Role of PET/CT in Management of Early Lung Adenocarcinoma, *American Journal of Roentgenology* (2019). [DOI: 10.2214/AJR.19.21585](https://doi.org/10.2214/AJR.19.21585)

Provided by American Roentgen Ray Society

Citation: PET/CT plays role in lung adenocarcinoma management (2019, December 16) retrieved 27 April 2024 from <https://medicalxpress.com/news/2019-12-petct-role-lung-adenocarcinoma.html>

This document is subject to copyright. Apart from any fair dealing for the purpose of private study or research, no part may be reproduced without the written permission. The content is provided for information purposes only.