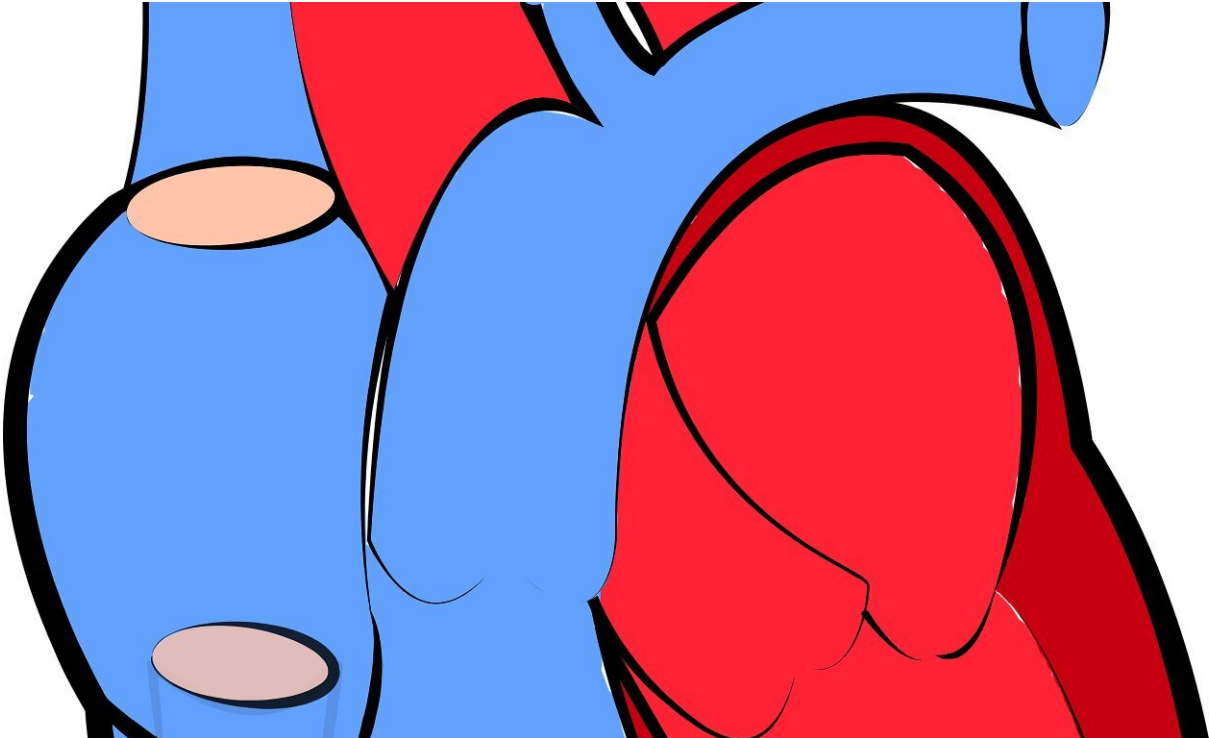


Is it bloating or is it a heart attack?

April 15 2020



Credit: CC0 Public Domain

A patient in the hospital for metastatic Hodgkin lymphoma with significant abdominal distention displayed sudden onset of ST-segment elevations—often an indicator of a heart attack—however the heart attack symptoms improved when the cardiovascular care team pressed on the abdomen during a standard exam, according to a case published in *JACC: Case Reports*.

"It is important to be aware that, while rare, acute gastrointestinal distention can cause ST-segment changes on an ECG. Clinicians must distinguish these cases from true heart attacks to prevent unnecessary treatment and invasive procedures whenever possible," said Enrique Ostrzega, MD, a cardiologist at the University of Southern California and the senior author of the case report.

Clinicians at the University of Southern California, Los Angeles, admitted a previously healthy 41-year-old male with three weeks of lower extremity swelling, fatigue and shortness of breath. He was taken to the [intensive care unit](#) (ICU) and later diagnosed with metastatic Hodgkin lymphoma.

While under sedation on a ventilator in the ICU, the patient's cardiac monitor displayed sudden onset of ST-segment elevation. The ST segment is the interval between ventricular depolarization and repolarization of the heartbeat on an electrocardiogram (ECG). Elevation of this segment can be a sign of a heart attack and is typically known as a "STEMI" (ST-Elevation Myocardial Infarction), which is a serious and high-risk presentation of a heart attack. An ECG in this case was interpreted by a computer algorithm as a heart attack, leading the treating clinicians to call for an emergent cardiology consult.

The patient's [physical examination](#) showed significant abdominal distention. When an ultrasound probe was placed on the patient's upper abdomen, the previously noted ST-segment elevations abruptly resolved on the cardiac monitor. These dynamic changes were confirmed with an ECG. There was immediate resolution of the ST-segment elevation when gentle palpation of the abdomen was performed. The consulting cardiology team suspected the cause may be related to the patient's abdominal distention and performed an abdominal X-ray which revealed significant gastric distention. After a [nasogastric tube](#) was placed for gastric decompression an ECG confirmed resolution of ST-segment

elevations with no further documented ST-segment abnormalities or evidence of cardiac dysfunction.

According to the report, when presented with an atypical case of ST-segment elevation on ECG, thorough examination and history are vital as other disorders can mimic a STEMI pattern on ECG. Some noncardiac causes of ST-segment [elevation](#) include pancreatitis, community-acquired pneumonia and intracranial bleeding.

In most previously reported cases of gastrointestinal distention causing a STEMI pattern on ECG, [coronary angiography](#) confirmed no evidence of obstructive coronary artery disease, and in all reported cases it improved with management and resolution of the underlying gastrointestinal issue. According to the report authors, to their knowledge this is the first case where a direct physical maneuver (abdominal palpation) elicited an acute reversal of ST-segment elevations. They believe the gastric distention led to a direct compressive effect on the [heart](#) and the application of mild pressure on the abdomen relieved or shifted the effect.

"Careful clinical examination and setting up the correct differential diagnosis is the cornerstone of the treatment of every patient. Here—starting from an important observation— [the authors] treated the patient without needing interventional procedures," said Julia Grapsa, MD, Ph.D., FACC, editor-in-chief of *JACC: Case Reports*.

More information: *JACC: Case Reports*, [DOI: 10.1016/j.jaccas.2020.02.016](#)

Provided by American College of Cardiology

Citation: Is it bloating or is it a heart attack? (2020, April 15) retrieved 23 April 2024 from <https://medicalxpress.com/news/2020-04-bloating-heart.html>

This document is subject to copyright. Apart from any fair dealing for the purpose of private study or research, no part may be reproduced without the written permission. The content is provided for information purposes only.