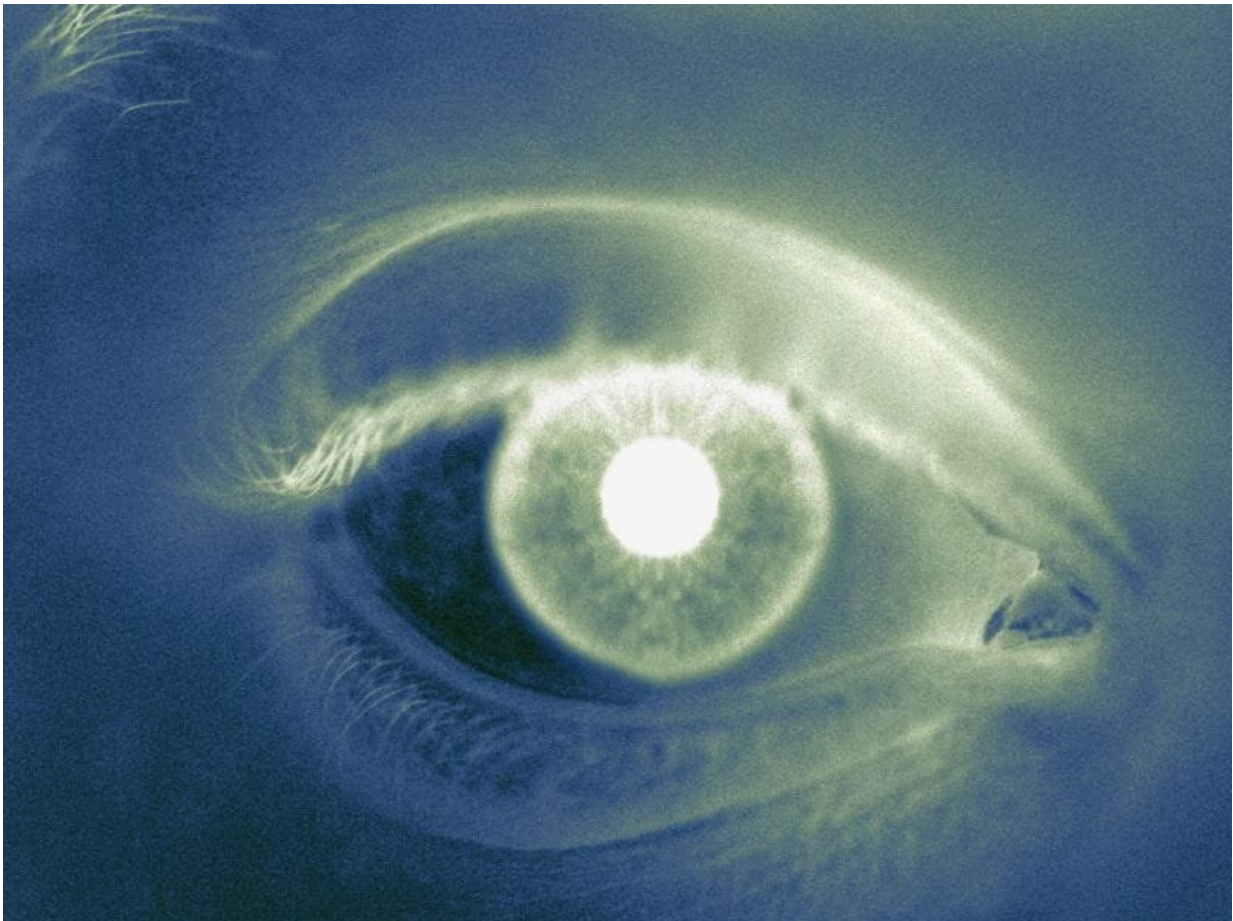


Ocular abnormalities seen in one-third of COVID-19 patients

April 1 2020



(HealthDay)—About one-third of patients with coronavirus disease 2019

(COVID-19) have ocular abnormalities, according to a brief report published online March 31 in *JAMA Ophthalmology*.

Ping Wu, M.D., from the Yichang Central People's Hospital in China, and colleagues examined ocular manifestations and viral prevalence in the conjunctiva in a case series of 38 patients with clinically confirmed COVID-19 treated from Feb. 9 to 15, 2020. The ocular signs and symptoms and results of blood tests and reverse-transcriptase polymerase chain reaction (RT-PCR) from nasopharyngeal and conjunctival swabs for severe acute respiratory syndrome coronavirus 2 (SARS-CoV-2) were analyzed.

The researchers found that 28 of the patients had positive findings for COVID-19 on RT-PCR from nasopharyngeal swabs, and two of these patients had positive findings for SARS-CoV-2 in their conjunctival specimens as well. Ocular manifestations consistent with conjunctivitis, including conjunctival hyperemia, chemosis, epiphora, or increased secretions were seen in 12 patients (31.6 percent). Compared with those without ocular symptoms, patients with ocular symptoms were more likely to have higher white blood cell count and neutrophil count and higher levels of procalcitonin, C-reactive protein, and lactate dehydrogenase. Eleven of 12 patients with ocular abnormalities had positive results for SARS-CoV-2 on nasopharyngeal RT-PCR; two of these had positive results for SARS-CoV-2 on conjunctival and nasopharyngeal swabs.

"These preliminary results are shared in an effort to inform ophthalmologists and others around the world regarding ocular symptoms with COVID-19," the authors write.

More information: [Abstract/Full Text](#)
[Editorial](#)

Copyright © 2020 [HealthDay](#). All rights reserved.

Citation: Ocular abnormalities seen in one-third of COVID-19 patients (2020, April 1) retrieved 23 May 2024 from <https://medicalxpress.com/news/2020-04-ocular-abnormalities-one-third-covid-patients.html>

This document is subject to copyright. Apart from any fair dealing for the purpose of private study or research, no part may be reproduced without the written permission. The content is provided for information purposes only.