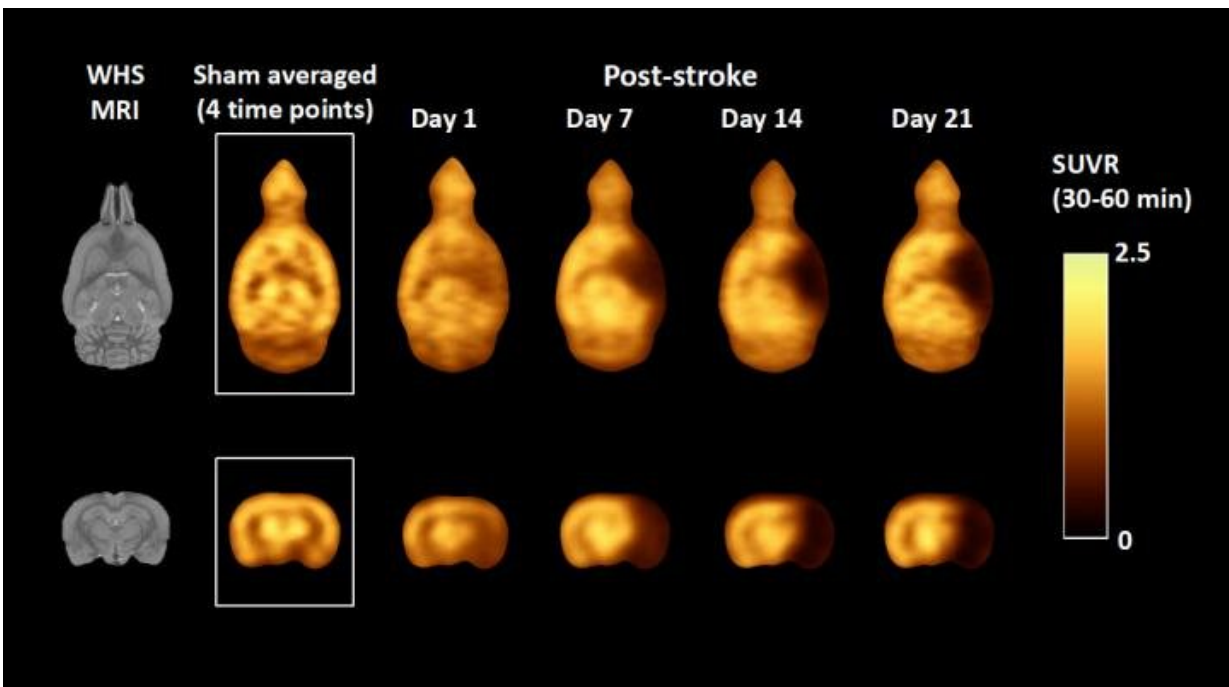


# Novel radiotracer measures synaptic activity after stroke

July 13 2020



Average standardized uptake value ratio PET images of stroke rat model over time as compared to a sham rat using mean cerebellum as the reference. Credit: T Toyonaga and X Lyu, Yale University, New Haven CT.

A new radiotracer,  $^{18}\text{F}$ -SynVesT-2, can directly assess synaptic density changes in the brain, providing an objective and quantitative measure of disease progression after stroke. Research presented at the Society of Nuclear Medicine and Molecular Imaging 2020 Annual Meeting shows

that the radiotracer may also offer a primary endpoint to evaluate treatment efficacy of novel therapeutics for stroke in clinical trials.

Current positron emission tomography (PET) imaging of [stroke](#) focuses on the measurement of oxygen or glucose metabolism. 18F-FDG PET has been used to probe brain tissue viability after [acute ischemic stroke](#), but transient hyperglycemia, a common phenomenon in acute stroke patients, affects FDG uptake and thereby confounds its interpretation. "Because synapse is a crucial microstructure for brain functions and synaptic deficit is a hallmark of stroke, we developed a new imaging method to assess synapses directly, providing an alternative to measuring metabolism to determine stroke progression," said Xueying Lyu, postgraduate research associate at Yale University School of Medicine in New Haven, Connecticut.

Researchers utilized a rat model of stroke (established through a middle cerebral artery occlusion procedure followed by reperfusion) to test the 18F-SynVesT-2 radiotracer. A total of six stroke model rats underwent weekly 18F-SynVesT-2 PET scans for four weeks, starting at one day post-reperfusion. Image analysis was conducted and standardized uptake values (SUV) were generated for the hippocampus, cerebellum, neocortex and thalamus. The SUVs of affected and non-affected sides of the brain were compared by calculating ipsi- to contralateral ratios, and the volume of lesion was assessed using SUV ratio normalized by the cerebellum, after smoothing, masking, subtracting, thresholding and binarizing.

18F-SynVesT-2 PET imaging successfully detected synapse loss in the rat model of stroke and tracked disease progression via lesion quantification. Synapse loss occurred mainly in the hippocampus, thalamus and neocortex rather than the cerebellum. The most significant loss of synapses was observed to occur during the first week post-reperfusion.

"This is the first direct demonstration of synaptic changes following stroke and has shown that the synaptic protein SV2A is a potential biomarker for tissue viability," noted Lyu. "Information on tissue viability is valuable to detect stroke early and to evaluate therapeutic efficacy and recovery. We hope to help stroke patients by bringing this SV2A PET imaging method to clinical settings in the near future."

According to the Centers for Disease Control and Prevention, more than 175,000 strokes occur each year in the United States, killing 140,000 Americans. It is a leading cause of long-term disability and costs the U.S. healthcare system an estimated \$34 billion annually in health care services, treatment and lost time at work.

Provided by Society of Nuclear Medicine and Molecular Imaging

Citation: Novel radiotracer measures synaptic activity after stroke (2020, July 13) retrieved 25 April 2024 from <https://medicalxpress.com/news/2020-07-radiotracer-synaptic.html>

This document is subject to copyright. Apart from any fair dealing for the purpose of private study or research, no part may be reproduced without the written permission. The content is provided for information purposes only.