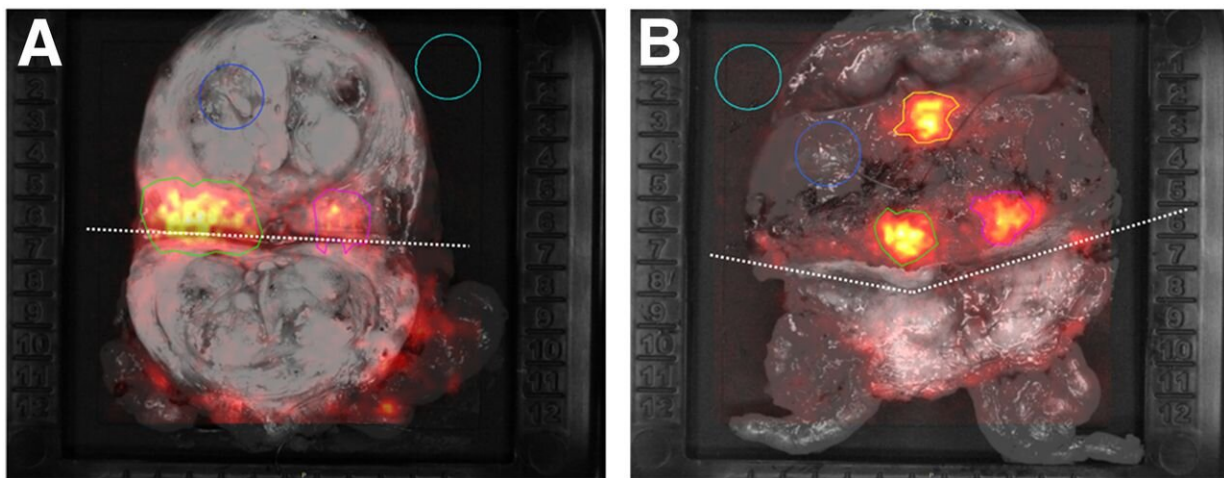


# Cerenkov luminescence imaging identifies surgical margin status in radical prostatectomy

October 7 2020



Grey-scale photographic images overlaid with Cerenkov signals. Incised prostate gland specimen of patient number 1 (A) and 2 (B). In each image the ROIs are encircled. The incision is marked with a dotted line. The light blue ROI (area of empty specimen tray) and dark blue ROI (area of normal prostate tissue) were used as empty background and tissue background, respectively. The green ROI (lesion 1) and pink ROI (lesion 2) show an increased signal; histopathological analysis confirmed cancer tissue in these areas. The orange ROI in image B shows an increased signal from an area without cancer cells. Credit: Society of Nuclear Medicine and Molecular Imaging

A new intraoperative imaging technique, Cerenkov luminescence

imaging (CLI), can accurately assess surgical margins during radical prostatectomy, according to first-in-human research published in the October issue of the *Journal of Nuclear Medicine*. The feasibility study showed that <sup>68</sup>Ga-PSMA CLI can image the entire excised prostate specimen's surface to detect prostate cancer tissue at the resection margin.

Radical prostatectomy is one of the primary treatment options for men with localized [prostate cancer](#). The goal of a [radical prostatectomy](#) is to completely resect the prostate without positive surgical margins. Incomplete removal of the [cancer](#) tissue during radical prostatectomy is often associated with poorer patient outcomes, including increased likelihood of recurrence and prostate cancer-related mortality.

Prostate-specific membrane antigen (PSMA) ligand positron emission tomography (PET) has emerged as an accurate tool to detect prostate cancer both in primary staging and at time of biochemical recurrence. As PET imaging agents also emit optical photons via a phenomenon called Cerenkov luminescence, researchers sought to evaluate the feasibility and diagnostic accuracy of CLI in detecting prostate cancer.

"Intraoperative radioguidance with CLI may help surgeons in the detection of extracapsular extension, positive surgical margins and lymph node metastases with the aim of increasing surgical precision," stated Christopher Darr, Ph.D., resident at the Department of Urology of the University Medical Center Essen in Essen, Germany. "The intraoperative use of CLI would allow the examination of the entire prostate surface and provide the surgeon with real-time feedback on the resection margins."

The single-center study included 10 patients with high-risk primary prostate cancer. <sup>68</sup>Ga-PSMA PET scans were performed followed by radical prostatectomy and intraoperative CLI of the excised prostate.

CLI images were analyzed postoperatively to determine regions of interest based on signal intensity, and tumor-to-background ratios were calculated. CLI tumor margin assessment was performed by analyzing elevated signals at the surface of the intact prostate images. To determine accuracy, tumor margin status as detected by CLI was compared to postoperative histopathology.

Tumor cells were successfully detected on the incised prostate CLI images and confirmed by histopathology. Three patients had positive surgical margins, and in two of the patients, elevated signal levels enabled correct identification on CLI. Overall, 25 out of 35 CLI regions of interest proved to visualize tumor signaling according to standard histopathology.

Boris A. Hadaschik, Ph.D., director of the Clinic for Urology of the University Medical Center Essen, added, "Radical prostatectomy could achieve significantly higher accuracy and oncological safety, especially in patients with high-risk prostate cancer, through the intraoperative use of radioligands that specifically detect prostate cancer cells. In the future, a targeted resection of [lymph node metastases](#) could also be performed in this way. This new imaging combines urologists and nuclear medicine specialists in the local treatment of patients with [prostate](#) cancer."

**More information:** Christopher Darr et al, Intraoperative 68Ga-PSMA Cerenkov Luminescence Imaging for Surgical Margins in Radical Prostatectomy: A Feasibility Study, *Journal of Nuclear Medicine* (2020). [DOI: 10.2967/jnumed.119.240424](https://doi.org/10.2967/jnumed.119.240424)

Provided by Society of Nuclear Medicine and Molecular Imaging

Citation: Cerenkov luminescence imaging identifies surgical margin status in radical prostatectomy (2020, October 7) retrieved 11 May 2024 from <https://medicalxpress.com/news/2020-10-cerenkov-luminescence-imaging-surgical-margin.html>

This document is subject to copyright. Apart from any fair dealing for the purpose of private study or research, no part may be reproduced without the written permission. The content is provided for information purposes only.