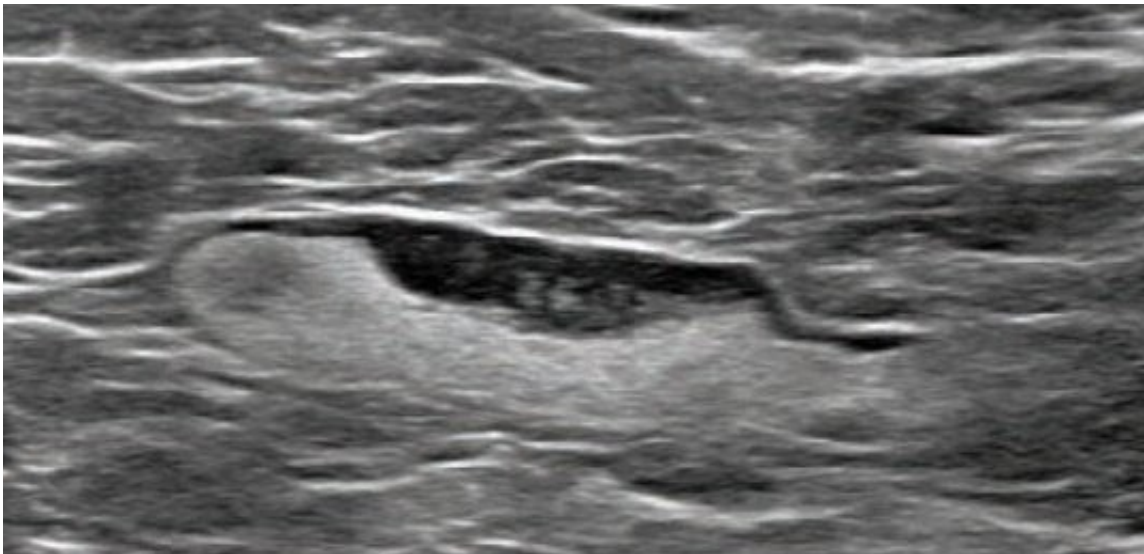


COVID-19 vaccination axillary adenopathy detected during breast imaging

February 24 2021



Screening mammogram and US demonstrated unilateral left axillary lymph node with cortical thickness of 5 mm on ultrasound (not shown). BI-RADS category 0 was assigned. Ultrasound from diagnostic work-up performed 7 days later showed no change in lymph node size. BI-RADS 3 was assigned. Credit: American Roentgen Ray Society (ARRS), *American Journal of Roentgenology* (AJR)

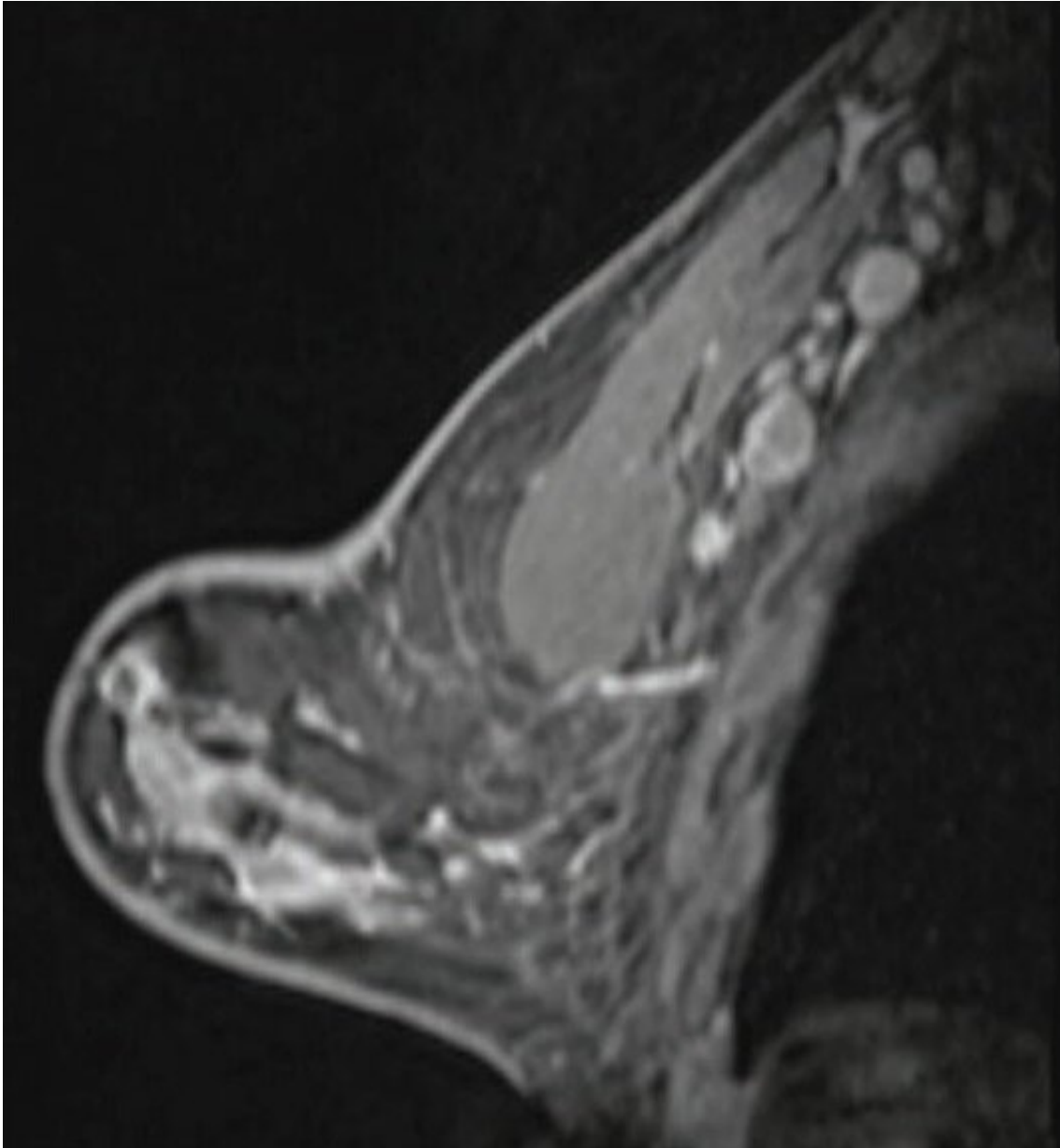
An open-access article in ARRS' *American Journal of Roentgenology* (AJR) describes the clinical and imaging features of axillary adenopathy detected during screening or diagnostic breast imaging after recent coronavirus disease (COVID-19) vaccination to inform the development of follow-up recommendations.

Shabnam Mortazavi of the University of California at Los Angeles reviewed [electronic medical records](#) to identify women with post-COVID-19 vaccination adenopathy found from December 2020 to February 2021. For mammography, Mortazavi considered a node abnormal when its size, shape, or density was deemed disproportionate to other axillary nodes (ipsilateral or contralateral). On ultrasound, she deemed a node abnormal based on subjective assessment for cortical abnormalities, including focal or diffuse thickening greater than 3 mm, as well as nodal prominence compared to the contralateral axilla (when available). For MRI, Mortazavi considered a node abnormal when asymmetric in size and/or number to the contralateral axilla.

Twenty-three women exhibited axillary adenopathy ipsilateral to the vaccinated arm on [screening](#) or diagnostic breast imaging, and according to Mortazavi, "13% were symptomatic (axillary lump with possible tenderness)." Meanwhile, the adenopathy was detected incidentally on screening breast imaging in 43% (mammography, 5; ultrasound, 2; both mammography and ultrasound, 1; high-risk screening MRI, 2) and on [diagnostic imaging](#) for other reasons in 43% (BI-RADS 3 follow-up for breast finding, 3; screening callback for other reason, 2; non-axillary breast pain or lump, 5). Noting that the median interval between the first vaccine dose and imaging showing the abnormal node was 9.5 days, Mortazavi's results counted a total of 57% of women with one abnormal node. BI-RADS 2 was assigned in one woman, BI-RADS 3 in 21 (ultrasound in 4-24 weeks), and BI-RADS 4 in one.

"The largest sample to our knowledge of COVID-19 vaccine associated axillary adenopathy on imaging," Mortazavi also wrote, "this study highlights axillary adenopathy ipsilateral to the vaccinated arm with Pfizer-BioNTech or Moderna COVID-19 vaccine as a potential reactive process with which radiologists must be familiar." Ultimately, vaccination date and laterality are critical to optimize assessment and management of imaging-detected axillary adenopathy in women with

otherwise normal [breast](#) imaging.



Sagittal T1-weighted fat-saturated contrast-enhanced MRI shows extensive unilateral left level I-II axillary adenopathy. BI-RADS 3 was assigned. Credit: American Roentgen Ray Society (ARRS), *American Journal of Roentgenology* (AJR)

More information: Shabnam Mortazavi, Coronavirus Disease (COVID-19) Vaccination Associated Axillary Adenopathy: Imaging Findings and Follow-Up Recommendations in 23 Women, *American Journal of Roentgenology* (2021). [DOI: 10.2214/AJR.21.25651](https://doi.org/10.2214/AJR.21.25651)

Provided by American Roentgen Ray Society

Citation: COVID-19 vaccination axillary adenopathy detected during breast imaging (2021, February 24) retrieved 23 May 2024 from <https://medicalxpress.com/news/2021-02-covid-vaccination-axillary-adenopathy-breast.html>

This document is subject to copyright. Apart from any fair dealing for the purpose of private study or research, no part may be reproduced without the written permission. The content is provided for information purposes only.