

Using contrast MRI after a heart attack could increase survival

May 11 2021

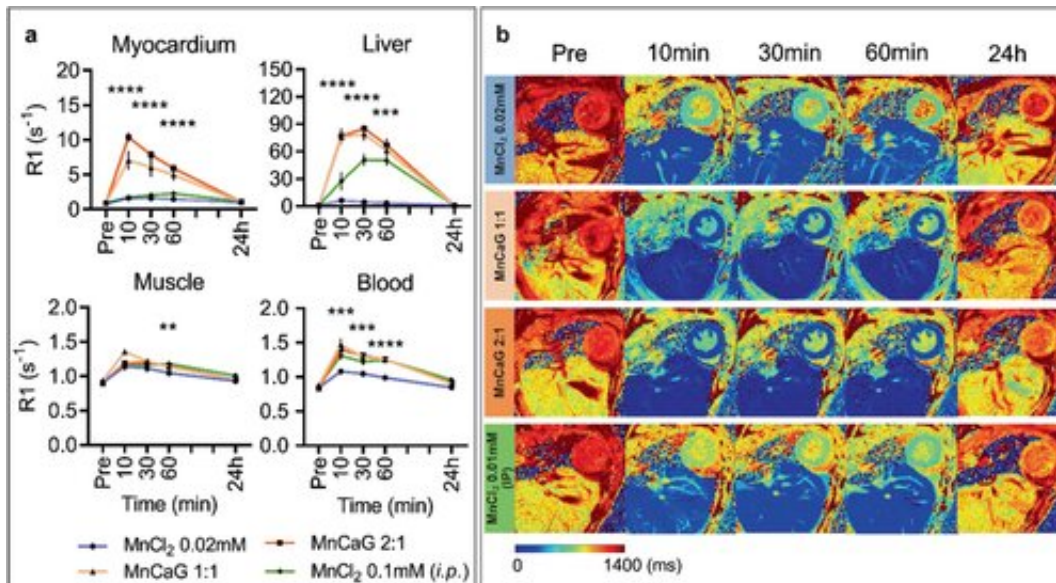


Figure 2 Time course of manganese uptake in control mice. a) R1 values (mean \pm SEM) in myocardium, liver, muscle, and blood at baseline, 10, 30, 60 min and 24 h post injection of 1) 0.02 mM MnCl₂ i.v. (n = 6); 2) 0.1 mM MnCl₂ + 0.1 mM CaG i.v. [MnCaG1:1] (n = 5); 3) 0.1 mM MnCl₂ + 0.05 mM CaG i.v. [mnCaG2:1] (n = 5); or 4) 0.1 mM MnCl₂ i.p. (n = 5). Data were analyzed by one-way ANOVA. Myocardium 10, 30, and 60 min (****p

Citation: Using contrast MRI after a heart attack could increase survival (2021, May 11)
retrieved 10 April 2024 from

<https://medicalxpress.com/news/2021-05-contrast-mri-heart-survival.html>

This document is subject to copyright. Apart from any fair dealing for the purpose of private study or research, no part may be reproduced without the written permission. The content is

provided for information purposes only.