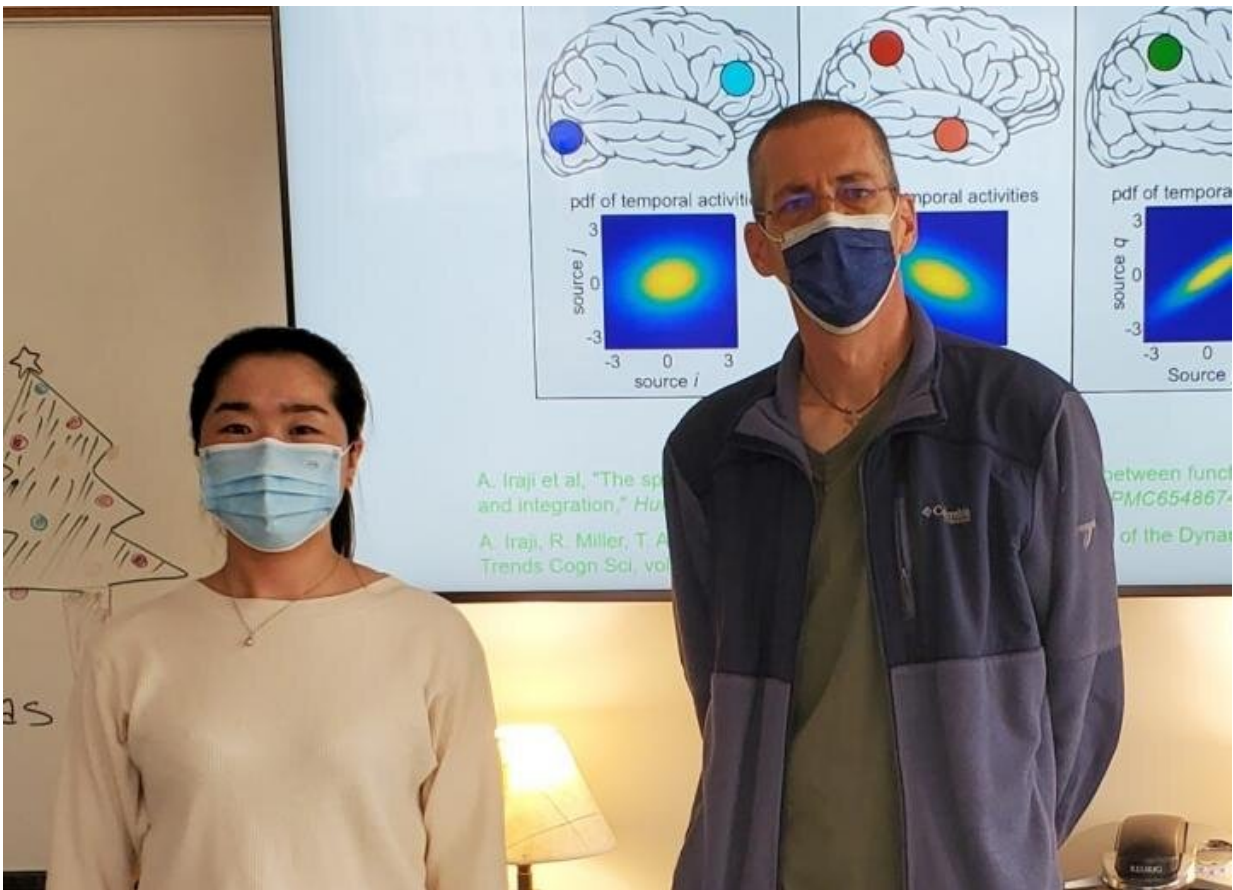


COVID-19 alters gray matter volume in the brain, new study shows

May 11 2021



Researchers Kuaikuai Duan and Vince Calhoun have found that neurological complications of Covid-19 patients may be linked to lower gray matter volume in the front region of the brain even six months after hospital discharge. Credit: Vince Calhoun, Georgia Tech

COVID-19 patients who receive oxygen therapy or experience fever show reduced gray matter volume in the frontal-temporal network of the brain, according to a new study led by researchers at Georgia State University and the Georgia Institute of Technology.

The study found lower [gray matter](#) volume in this brain region was associated with a higher level of disability among COVID-19 patients, even six months after hospital discharge.

Gray matter is vital for processing information in the brain and gray matter abnormality may affect how well neurons function and communicate. The study, published in the May 2021 issue of *Neurobiology of Stress*, indicates gray matter in the frontal network could represent a core region for brain involvement in COVID-19, even beyond damage related to clinical manifestations of the disease, such as stroke.

The researchers, who are affiliated with the Center for Translational Research in Neuroimaging and Data Science (TReNDS), analyzed computed tomography scans in 120 neurological patients, including 58 with acute COVID-19 and 62 without COVID-19, matched for age, gender and disease. They used source-based morphometry analysis, which boosts the statistical power for studies with a moderate sample size.

"Science has shown that the brain's structure affects its function, and abnormal brain imaging has emerged as a major feature of COVID-19," said Kuaikuai Duan, the study's first author, a graduate research assistant at TReNDS and Ph.D. student in Georgia Tech's School of Electrical and Computer Engineering. "Previous studies have examined how the brain is affected by COVID-19 using a univariate approach, but ours is the first to use a multivariate, data-driven approach to link these changes to specific COVID-19 characteristics (for example fever and lack of

oxygen) and outcome (disability level)."

The analysis showed patients with higher levels of disability had lower gray matter volume in the superior, medial and middle frontal gyri at discharge and six months later, even when controlling for cerebrovascular diseases. Gray matter volume in this region was also significantly reduced in patients receiving oxygen therapy compared to patients not receiving oxygen therapy. Patients with fever had a significant reduction in [gray matter volume](#) in the inferior and middle temporal gyri and the fusiform gyrus compared to patients without fever. The results suggest COVID-19 may affect the frontal-temporal network through fever or lack of oxygen.

Reduced gray matter in the superior, medial and middle frontal gyri was also present in patients with agitation compared to patients without agitation. This implies that gray matter changes in the frontal region of the brain may underlie the mood disturbances commonly exhibited by COVID-19 patients.

"Neurological complications are increasingly documented for patients with COVID-19," said Vince Calhoun, senior author of the study and director of TRENDS. Calhoun is Distinguished University Professor of Psychology at Georgia State and holds appointments in the School of Electrical and Computer Engineering at Georgia Tech and in neurology and psychiatry at Emory University. "A reduction of gray matter has also been shown to be present in other mood disorders such as schizophrenia and is likely related to the way that gray matter influences neuron function."

The study's findings demonstrate changes to the frontal-temporal network could be used as a biomarker to determine the likely prognosis of COVID-19 or evaluate treatment options for the disease. Next, the researchers hope to replicate the study on a larger sample size that

includes many types of [brain](#) scans and different populations of COVID-19 patients.

More information: Kuaikuai Duan et al, Alterations of frontal-temporal gray matter volume associate with clinical measures of older adults with COVID-19, *Neurobiology of Stress* (2021). [DOI: 10.1016/j.ynstr.2021.100326](#)

Provided by Georgia Institute of Technology

Citation: COVID-19 alters gray matter volume in the brain, new study shows (2021, May 11) retrieved 4 May 2024 from <https://medicalxpress.com/news/2021-05-covid-gray-volume-brain.html>

This document is subject to copyright. Apart from any fair dealing for the purpose of private study or research, no part may be reproduced without the written permission. The content is provided for information purposes only.