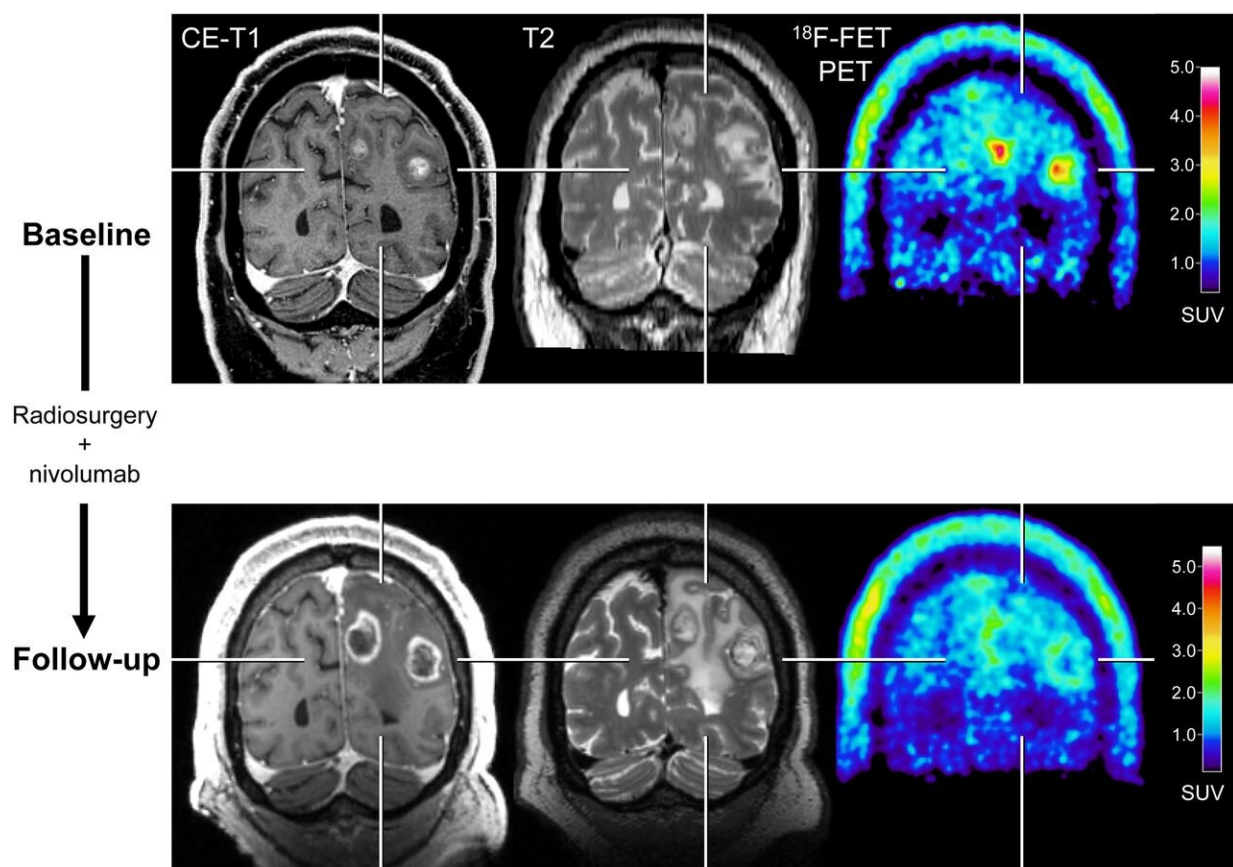


# With new treatments, PET imaging adds valuable information to brain metastasis monitoring

May 4 2021



After radiosurgery concurrent with nivolumab in 59-year-old patient with melanoma BM (patient 1; Supplemental Tables 3 and 5), <sup>18</sup>F-FET PET at follow-up 12 weeks after treatment initiation (bottom row) shows significant decrease of metabolic activity (TBRmean, -28%) compared with baseline (top row), although MRI changes were consistent with progression according to iRANO

criteria. Reduction of metabolic activity was associated with stable clinical course over 10 months. CE = contrast-enhanced. Credit: Society of Nuclear Medicine and Molecular Imaging

For patients with brain metastases, amino acid positron emission tomography (PET) can provide valuable information about the effectiveness of state-of-the-art treatments. When treatment monitoring with contrast-enhanced magnetic resonance imaging (MRI) is unclear, adding 18F-FET PET can help to accurately diagnose recurring brain metastases and reliably assess patient response. This research was published in *The Journal of Nuclear Medicine*.

Newer treatment options for patients with brain metastases—such as immune checkpoint inhibitors and targeted therapies—are effective, but can cause a variety of side effects. As a result, imaging findings on contrast-enhanced MRI can be highly variable, and it can be difficult to tell whether a treatment is working.

"Essentially, these new treatments have requirements of brain imaging which cannot be met by conventional MRI," said Norbert Galldiks, MD, professor of neurology, neurologist and neuro-oncologist at the University Hospital Cologne and Research Center in Juelich, Germany. "In our study, we tried to determine if adding 18F-FET PET could help to overcome some of these imaging challenges."

The [retrospective study](#) included melanoma and lung cancer patients with brain metastases who had been treated with immune checkpoint inhibitors or targeted therapy alone or in combination with radiotherapy. 18F-FET PET imaging was shown to be a useful method when conventional MRI was inconclusive. It could correctly diagnose brain metastasis relapses and identify patients who were responding to

treatment and those who were not.

"In cases of ambiguous MRI findings, supplemental FET PET is helpful for treatment monitoring. It provides physicians with a longer time window for subsequent patient management and allows them to optimize the treatment strategy for each individual patient," noted Galldiks.

"Since this approach is so accurate, it has the potential to influence clinical decision making. This may help to reduce the number of invasive procedures and limit overtreatment for a considerable number of seriously ill patients with [brain metastases](#)."

**More information:** Norbert Galldiks et al, Treatment Monitoring of Immunotherapy and Targeted Therapy Using 18F-FET PET in Patients with Melanoma and Lung Cancer Brain Metastases: Initial Experiences, *Journal of Nuclear Medicine* (2020). [DOI: 10.2967/jnumed.120.248278](https://doi.org/10.2967/jnumed.120.248278)

Provided by Society of Nuclear Medicine and Molecular Imaging

Citation: With new treatments, PET imaging adds valuable information to brain metastasis monitoring (2021, May 4) retrieved 11 May 2024 from

<https://medicalxpress.com/news/2021-05-treatments-pet-imaging-valuable-brain.html>

<p>This document is subject to copyright. Apart from any fair dealing for the purpose of private study or research, no part may be reproduced without the written permission. The content is provided for information purposes only.</p>
--