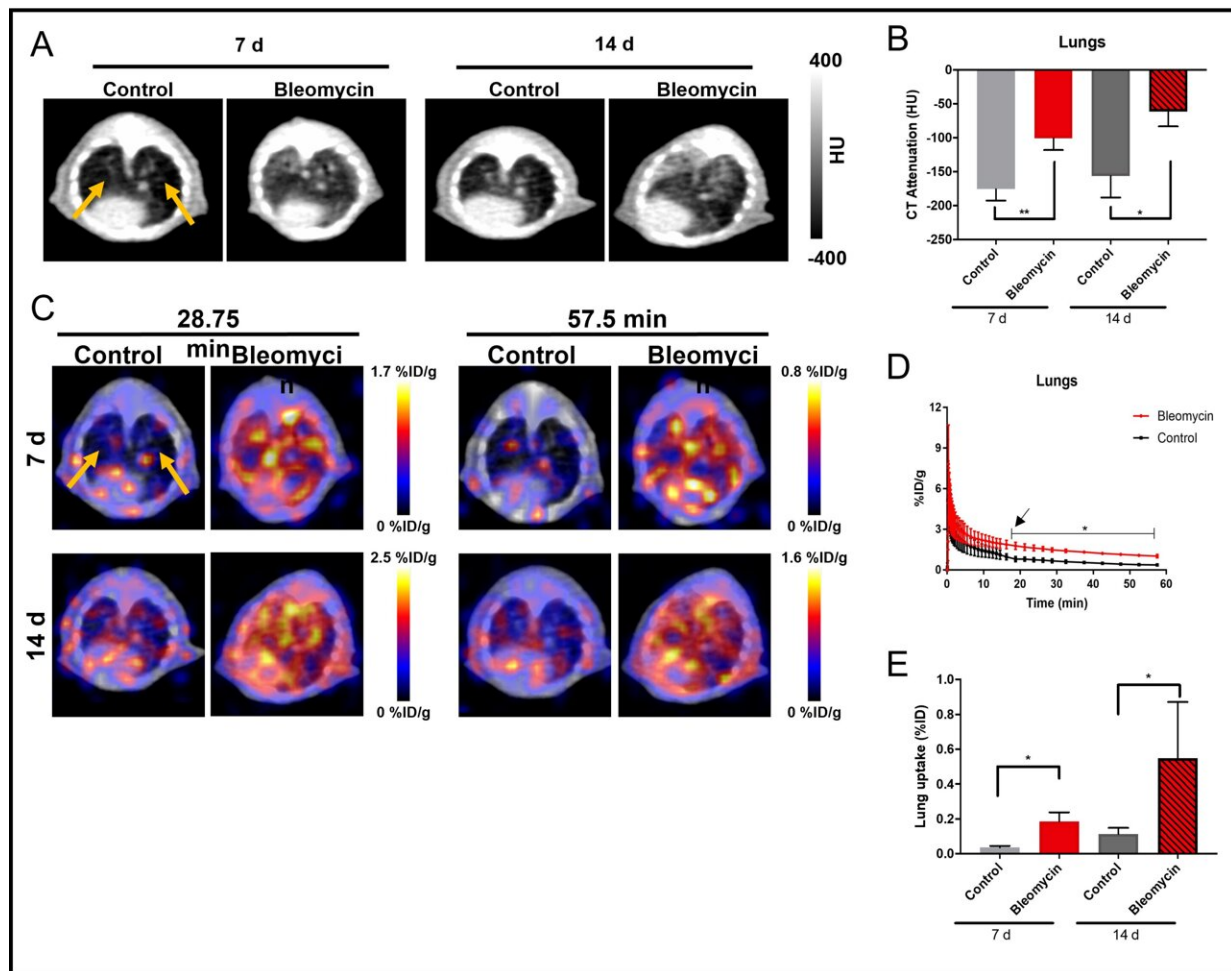


Radiotracer effective for detection and assessment of lung fibrosis

June 14 2021



A) Axial CT images through the mouse lungs at 7 and 14 days after intratracheal administration of bleomycin or saline (as a control), demonstrating increased lung fibrosis in the bleomycin group (white arrows). (B) CT attenuation histograms in Hounsfield units (HU) after lung segmentation demonstrate increased attenuation in the lungs in the bleomycin group than the control group

(p

Citation: Radiotracer effective for detection and assessment of lung fibrosis (2021, June 14)
retrieved 27 April 2024 from
<https://medicalxpress.com/news/2021-06-radiotracer-effective-lung-fibrosis.html>

This document is subject to copyright. Apart from any fair dealing for the purpose of private study or research, no part may be reproduced without the written permission. The content is provided for information purposes only.