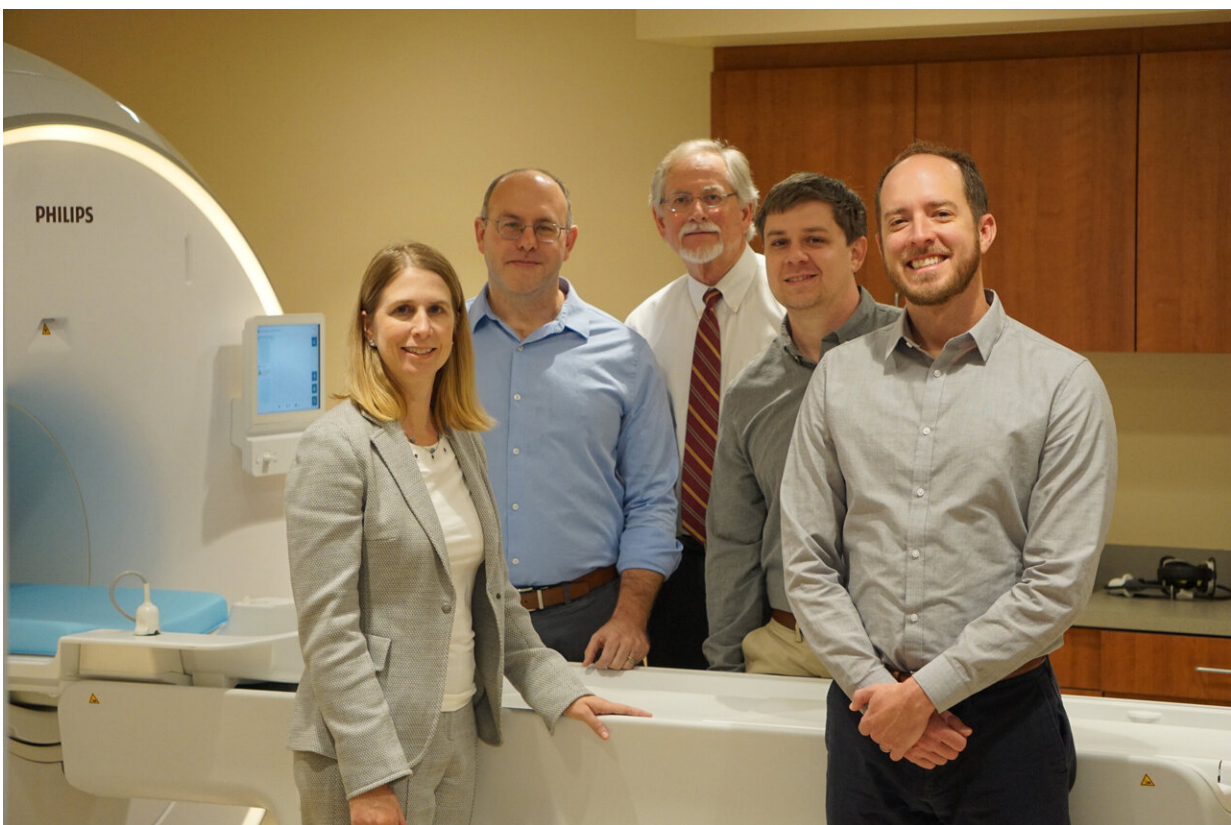


Study proves standardized protocol can support reliable MRI use for multisite pancreatic research

August 27 2021



The Multicenter Assessment of the Pancreas in Type 1 Diabetes (MAP-T1D) study, coordinated at VUMC, is the collaborative product of an international research team using MRI to investigate the pancreas in individuals with type 1 diabetes. Team members, from left, Melissa Hilmes, MD, Daniel Moore, MD, PhD, Alvin Powers, MD, Jon Williams, PhD, and Jack Virostko, PhD. (photo by Jessica Kimber, Vanderbilt University Medical Center). Credit: Vanderbilt

Researchers with the Vanderbilt Diabetes Research and Training Center (DRTC) at Vanderbilt University Medical Center led a multisite study which has demonstrated that, when controlled and standardized, quantitative magnetic resonance imaging (MRI) of the pancreas is highly reproducible when using different MRI hardware and software at different geographic locations.

This finding opens up a new approach to incorporating MRI into multisite clinical trials related to diabetes and other diseases impacting the pancreas. It is expected that adding the use of MRI following a strict protocol to the investigative toolbox for large, multisite studies will drive improved diagnosis and treatment of diseases impacting the pancreas, as well as better monitoring and understanding of disease progression.

The Multicenter Assessment of the Pancreas in Type 1 Diabetes (MAP-T1D) study, coordinated at VUMC, is the collaborative product of an international research team using MRI to investigate the pancreas in individuals with type 1 diabetes. The findings are published in the open access journal *PLOS ONE*.

"MRI is invaluable for diagnosing and monitoring many pancreatic disorders including chronic and acute pancreatitis, non-alcoholic fatty pancreas disease and pancreatic cancer," said VUMC site investigator Daniel Moore, Ph.D., MD, assistant professor of Pediatrics and Pathology, Microbiology and Immunology. "Also, in recent studies MRI has been used to better understand the progression of type 1 and type 2 diabetes as evidenced by changes in pancreas size.

"We know MRI can have important applications in future diabetes

research and ultimately clinical management of the disease so our developing, testing and then sharing a standardized pancreatic imaging protocol for MRI is a critical step to advance this field."

A key limitation in the use of MRI for studying the pancreas has been the inability to perform accurate, multisite studies of the pancreas using MRI imaging due to the great variability of the [images](#) produced by different MRI hardware and software. Also, while MRI imaging of the brain and solid tumors has benefited from multisite standardization, the pancreas is challenging to image due to its location deep within the abdomen, its irregular borders and the potential for artifacts or features that appear in the imaging that are not actually present in the body.

For the study, a "phantom," a carefully calibrated object that is scanned to evaluate the performance of an imaging device, was imaged at five clinical sites using different MRI hardware and software in order to develop a standardized MRI protocol.

Then, five healthy volunteers underwent MRI imaging at four of the study locations—Austin, Texas; Chicago; Denver; and Nashville, Tennessee—where different MRI equipment was used following the protocol. Measurements were taken for pancreas size, shape and other precise, quantitative factors typically used for disease diagnosis and progression.

John Virostko, an investigator in MAP-T1D and assistant professor of Diagnostic Medicine in the Dell Medical School at the University of Texas at Austin, designed the phantoms and coordinated the MRI image processing and analysis. Virostko was formerly at Vanderbilt University Institute of Imaging Science where he initiated MRI studies of the pancreas in type 1 diabetes and began this collaboration with Moore.

Using the standardized image processing resulted in reproducible

measurements with coefficients of variation less than 10%. There was no statistically significant difference in any measure across the MRI scanners or between any pair of scanners.

"We were able to show that by using a standardized MRI image acquisition and processing protocol, quantitative MRI of the pancreas performed at multiple locations can be very accurately reproduced," said Virostko. "Because of this, scientists throughout the world can follow this same protocol to incorporate MRI into multisite clinical trials comparing pancreas imaging measures and metabolic state in individuals with type 1 or type 2 diabetes," he said.

"This has positive implications for scientists investigating other diseases affecting the pancreas, and we're sharing this protocol universally to support future research," said Moore. "We hope scientists applying imaging to the pancreas will adopt a standardized protocol that will ultimately enable everyone to combine data from diverse studies and thereby accelerate progress."

The adoption of a standardized protocol will also enable the application of radiomics—a high-throughput, quantitative approach to imaging. Moving to an objective approach will support the application of new advanced analysis methods and will enable more precise analysis of these data without relying primarily on visual inspection of MRI scans of the pancreas, as has been the case for most clinical data to date, Virostko said.

VUMC is a clinical center for the Type 1 Diabetes TrialNet, an international network of academic institutions, endocrinologists, physicians, scientists and health care teams at the forefront of type 1 diabetes research. Through TrialNet, individuals are screened for specific autoantibodies or proteins produced by the immune system associated with type 1 diabetes. Persons with two or more autoantibodies

are now known to have stage 1 type 1 diabetes, but it is not known when they might progress to persistent high blood sugars and new onset symptomatic disease (stage 3).

The research team plans to next investigate whether [pancreas](#) size, documented by following the MRI protocol, plays a role in the rate of type 1 diabetes progression. Because each clinical site has relatively few persons at early type 1 [diabetes](#) stages, using the standardized MRI approach will help the team integrate data from around the world.

This collaborative study was conducted by researchers from VUMC, University of Texas at Austin, the Barbara Davis Center for Diabetes at the University of Colorado, University of Chicago and St. Vincent's Medical Research Institute at the University of Melbourne.

More information: John Virostko et al, Development of a standardized MRI protocol for pancreas assessment in humans, *PLOS ONE* (2021). [DOI: 10.1371/journal.pone.0256029](https://doi.org/10.1371/journal.pone.0256029)

Provided by Vanderbilt University Medical Center

Citation: Study proves standardized protocol can support reliable MRI use for multisite pancreatic research (2021, August 27) retrieved 2 May 2024 from <https://medicalxpress.com/news/2021-08-standardized-protocol-reliable-mri-multisite.html>

This document is subject to copyright. Apart from any fair dealing for the purpose of private study or research, no part may be reproduced without the written permission. The content is provided for information purposes only.