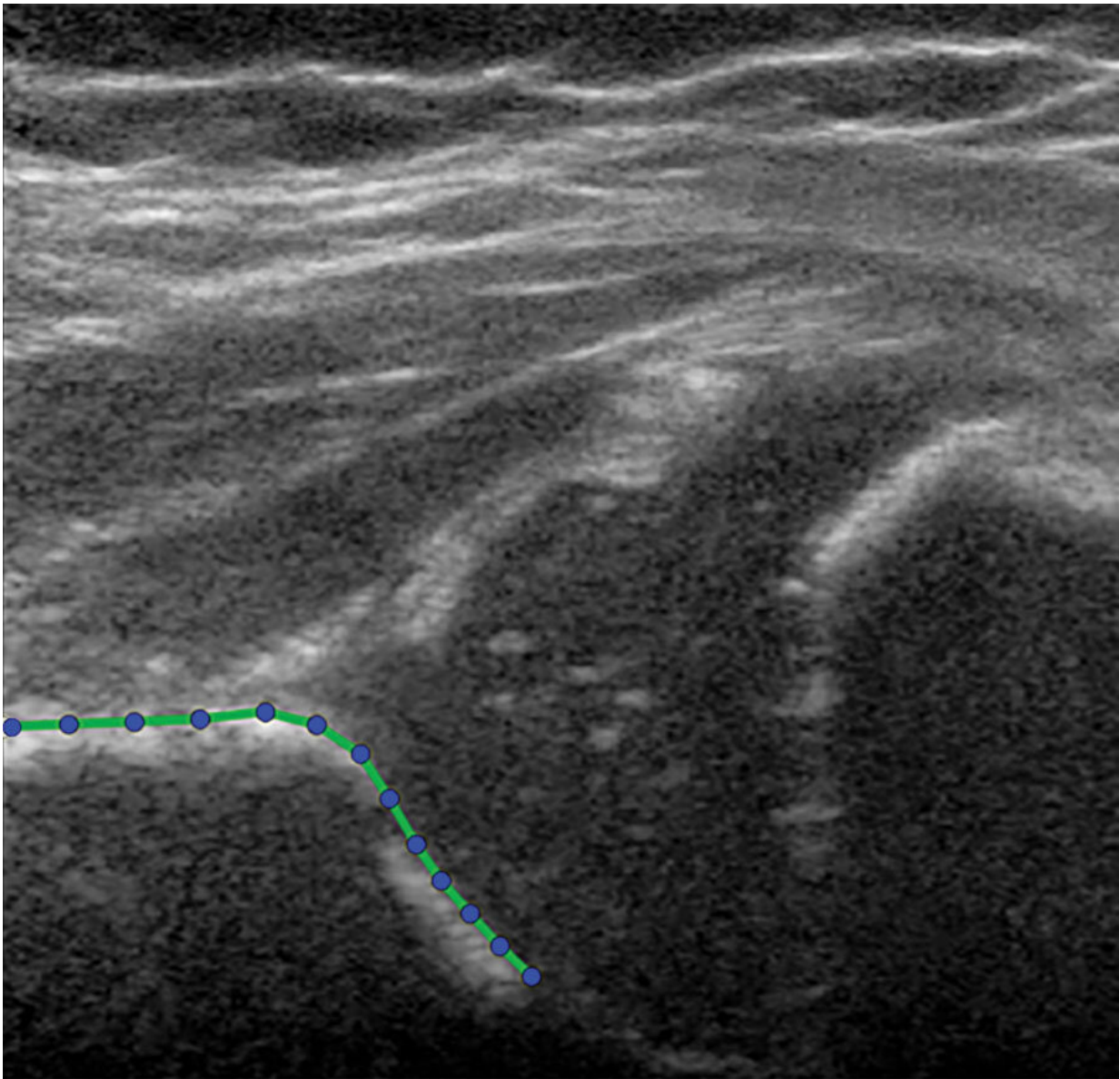


Ultrasound technique predicts hip dysplasia in infants

January 25 2022



Hip US image in a 3-month-old girl at baseline. No contrast material was used. The presented hip is outlined with the acetabular shape model, consisting of 13 points. Credit: Radiological Society of North America

A technique that uses ultrasound images to determine the depth and shape of the hip socket can accurately predict which infants with hip dysplasia will develop normal hip structure and which remain dysplastic, according to a study in *Radiology*. Researchers said statistical shape modeling improves on existing techniques and could spare many infants from unnecessary treatment.

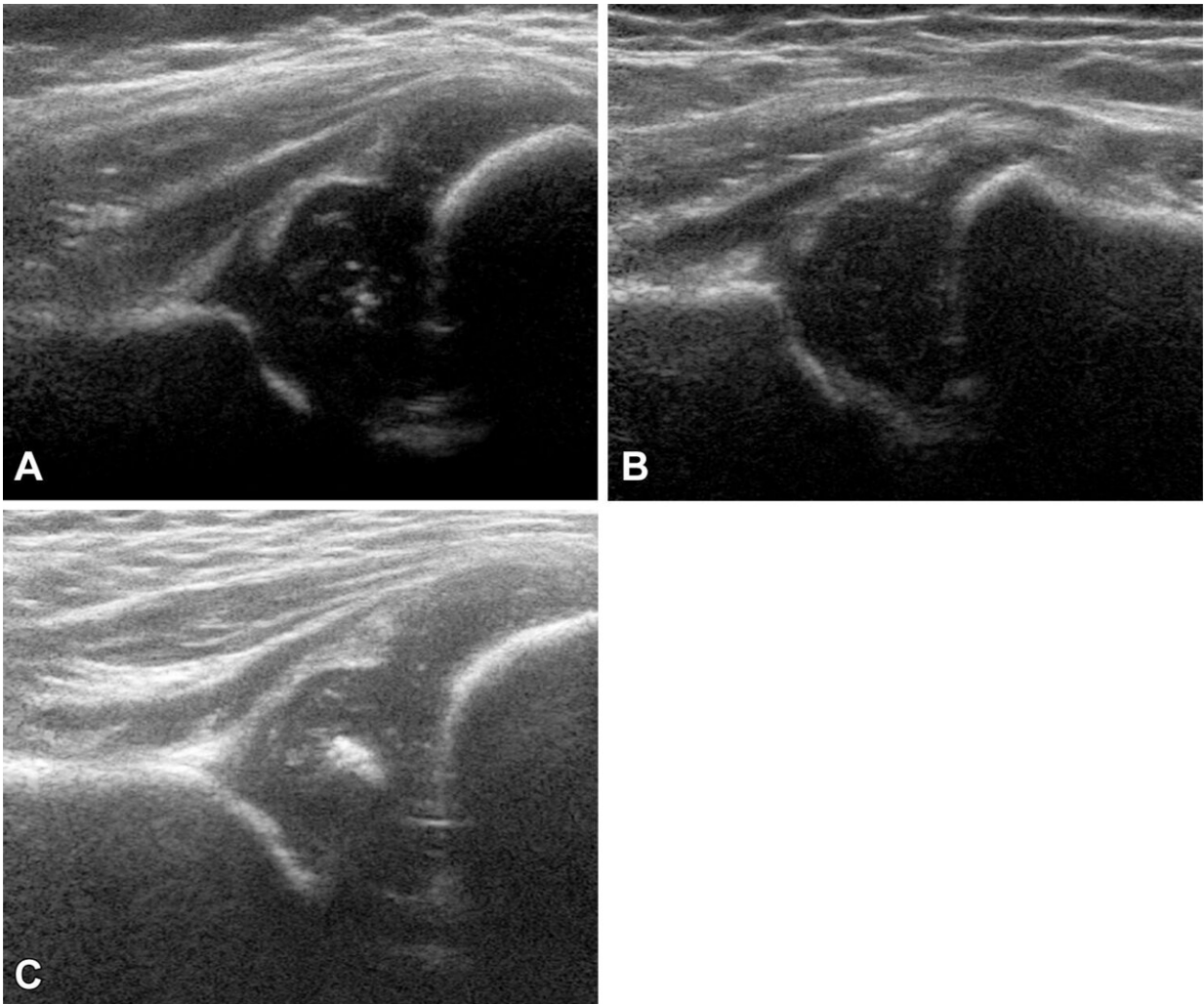
Developmental [dysplasia](#) of the hip occurs when the baby's hip socket is too shallow to cover the head of the thigh bone. In severe cases, the thigh bone can become dislocated from the hip entirely. According to the International Hip Dysplasia Institute, 1 in 10 infants are born with hip instability, meaning the hips can be wiggled in the socket because of loose ligaments. After birth, most will tighten up naturally. One in 100 infants will need treatment for hip dysplasia.

There is no consensus on how and when to treat stable hip dysplasia (Graf type 2, as determined by the Graf classification system). It is estimated that about 80% of stable Graf 2 hips will develop to normal without treatment. But since there is currently no way to differentiate those that will develop to normal in the future compared to those that will not, a large percentage of stable cases are likely to be overtreated, according to study senior author Ralph J. B. Sakkars, M.D., Ph.D., from the Department of Orthopedic Surgery at the University Medical Center Utrecht in Utrecht, the Netherlands. Overtreatment has significant drawbacks.

"The most important negative consequences of overtreatment are the

financial and logistical burdens for parents and society," Dr. Sakkers said. "Medical consequences of overtreatment are relatively rare, but the risk is not zero. If there is a rare medical consequence this would probably be avascular necrosis of the hip due to non-proper use of the treatment device."

Avascular necrosis is a disease that results from the temporary or permanent loss of blood supply to the bone.



Examples of hip US images obtained with mode 1; no contrast material was used. The presented hips were (A) -1.58 (girl), (B) $+0.11$ (girl), and (C) $+1.80$

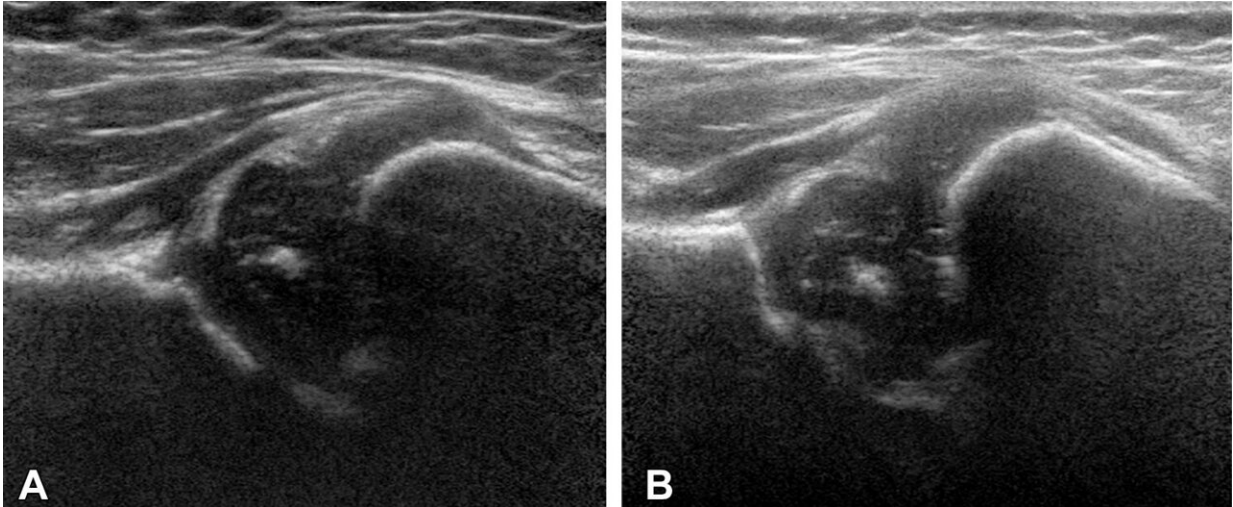
(boy) standard deviations from the mean shape. Credit: Radiological Society of North America

The Graf classification system is commonly used to evaluate hip dysplasia, but it has limitations. Patients are classified into groups based on acetabular angle appearance on [ultrasound](#) images. This angle is derived from the depth and [shape](#) of the socket of the hip bone where the head of the femur fits. The Graf system is reported to have a high variability and low agreement in all reported hip dysplasia metrics, and the ultrasound image quality and anatomic appearance of the hip can be affected by probe positioning.

Statistical shape modeling with ultrasound is an alternative method that quantifies the shape of the image of the hip with multiple reference points that each have an X and an Y coordinate in the 2D ultrasound image. It offers potential advantages over existing [predictive models](#).

"By quantifying the shape of the image of the hip with statistical shape modeling, significantly more data are extracted from the ultrasound images as compared to the current methods used," Dr. Sakkers said.

For the study, Dr. Sakkers and colleagues analyzed the predictive power of the technique in 97 infants with stable developmental dysplasia of the hip.



Examples of hip US images acquired with mode 2; no contrast material was used. The presented hips were (A) -1.83 (girl) and (B) $+2.12$ (girl) standard deviations from the mean shape. Credit: Radiological Society of North America

They developed statistical shape modeling on baseline [ultrasound images](#) and then correlated the model with persistent hip dysplasia on ultrasound after 12 weeks follow-up and residual hip dysplasia on pelvic X-rays around the age of one year.

The results showed that statistical shape modeling accurately predicted which hips developed to normal or remained dysplastic. It also identified hips that benefitted from treatment with the Pavlik harness, a soft splint that encourages normal development of the hip socket.

Although more research is needed to validate the proof of concept, the study findings support a future role for statistical shape modeling in the clinic.

"The method could be automated after validation, similarly to the

current automated determination of the skeletal age on X-rays of the hand," Dr. Sakkers said.

The researchers hope to prove the robustness of the method with additional research in other patient populations with stable [hip dysplasia](#) according to the Graf classification.

More information: Joshua M. Bonsel et al, Statistical Shape Modeling of US Images to Predict Hip Dysplasia Development in Infants, *Radiology* (2022). [DOI: 10.1148/radiol.211057](https://doi.org/10.1148/radiol.211057)

Provided by Radiological Society of North America

Citation: Ultrasound technique predicts hip dysplasia in infants (2022, January 25) retrieved 3 May 2024 from <https://medicalxpress.com/news/2022-01-ultrasound-technique-hip-dysplasia-infants.html>

<p>This document is subject to copyright. Apart from any fair dealing for the purpose of private study or research, no part may be reproduced without the written permission. The content is provided for information purposes only.</p>
--