

Molecular imaging uncovers effects of COVID-19 on the brain

March 17 2022

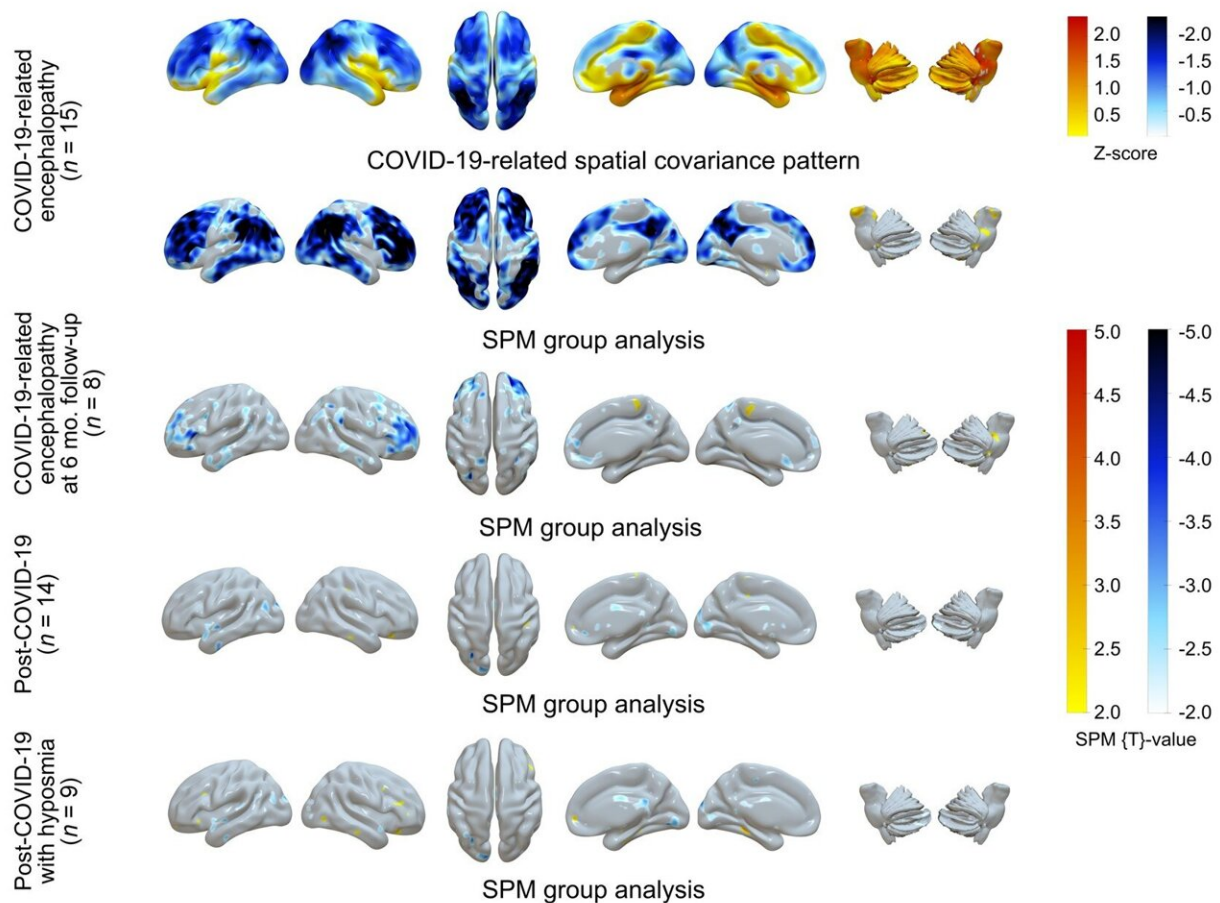


Figure 1. ^{18}F -FDG PET in COVID-19–related CNS disorders: Principal components analysis of spatial covariance pattern (first row) and statistical parametric mapping analysis of metabolic group differences (second to fifth rows) in patients with COVID-19–related encephalopathy, patients with post-COVID-19 syndrome, and patients with post-COVID-19 syndrome and hyposmia compared to healthy controls ($n=13$). Credit: Society of Nuclear

A significant number of COVID-19 neurological complications— such as fatigue, headache, and cognitive impairment—are ultimately reversible, according to new research summarized by the *Journal of Nuclear Medicine*. The comprehensive literature review of molecular imaging findings sheds light on how COVID-19 affects the brain and identifies important implications for other neurological conditions, like Parkinson's disease or Alzheimer's disease.

Neurological symptoms are present in roughly two-thirds of hospitalized COVID-19 patients. Symptoms include fatigue, loss of smell, attention problems and memory loss. Patients who have more severe COVID-19 cases, are older, or have pre-existing conditions are more likely to experience these neurological issues.

Molecular imaging with PET or SPECT has been used to determine how COVID-19 affects the brain; however, these scans often show conflicting results. To make sense of the data, researchers conducted a comprehensive, systematic and critical review of molecular imaging studies in neuropsychiatric COVID-19 cases.

Their report was structured according to neurological symptoms and how they developed over time. The five symptoms included in the report were encephalitis, Parkinsonism and other [neurodegenerative diseases](#), focal symptoms/lesions, encephalopathy, and post-COVID-19 syndrome. This helped the researchers to understand potential underlying (and most likely diverse) causes of the symptoms and to unravel discrepancies in the PET and SPECT literature.

"The presented studies are of high importance for patients struggling

with neurological or cognitive aftermaths of COVID-19," said Philipp T. Meyer, MD, Ph.D., head of the Department of Nuclear Medicine of the Medical Center–University of Freiburg, in Freiburg, Germany. "To the best of our knowledge there are no convincing studies clearly demonstrating relevant and irreversible brain damage, except for disease complications like brain infarcts and bleedings. Thus, from our perspective, in the vast majority of cases there is no reason to assume that reported impairments will be permanent and not responsive to treatment."

What are the implications of this research for the future of molecular imaging of COVID-19 [neurological symptoms](#)? First, there is a clear need for further well-designed studies. "These need to be prospective, recruit larger patient cohorts, follow accepted syndrome or stage definitions, and use proper methodology," noted Jonas A. Hosp, MD, attending physician of the Department of Neurology and Clinical Neuroscience of the Medical Center–University of Freiburg, in Freiburg, Germany. "Carefully designed studies of COVID-19 populations will be of great interest moving forward."

Second, there are several potential clinical applications of molecular imaging in COVID-19 patients with cognitive or neurological impairment. "It may be the case that COVID-19 unmasked or hastened a pre-existing neurodegenerative disease like Parkinson's or Alzheimer's," said Meyer. "Molecular imaging could be used to identify these patients."

More information: Philipp T Meyer et al, Molecular imaging findings on acute and long-term effects of COVID-19 on the brain: A systematic review, *Journal of Nuclear Medicine* (2022). [DOI: 10.2967/jnumed.121.263085](https://doi.org/10.2967/jnumed.121.263085)

Provided by Society of Nuclear Medicine

Citation: Molecular imaging uncovers effects of COVID-19 on the brain (2022, March 17)
retrieved 27 April 2024 from

<https://medicalxpress.com/news/2022-03-molecular-imaging-uncovers-effects-covid-.html>

This document is subject to copyright. Apart from any fair dealing for the purpose of private study or research, no part may be reproduced without the written permission. The content is provided for information purposes only.