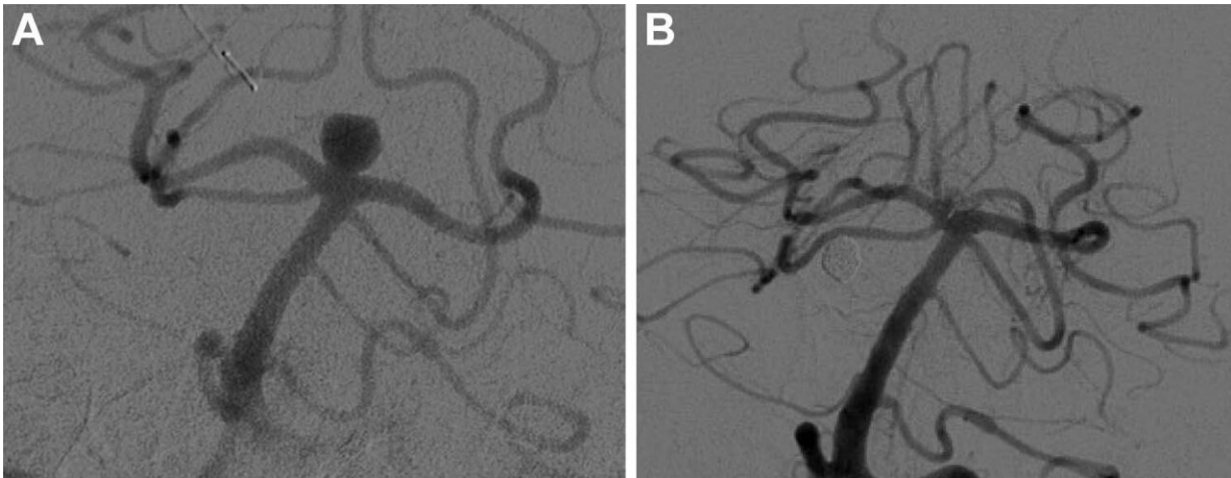


Novel treatment effective for sidewall brain aneurysm

April 19 2022



Digital subtraction angiography images show basilar tip aneurysm (A) before and (B) at last follow-up after Woven EndoBridge device placement. Credit: Radiological Society of North America

A novel mesh plug that has been traditionally used to treat brain aneurysms occurring where the blood vessels branch out was found to be equally effective in treating aneurysms on the side of the vessel, according to a study in the journal *Radiology*.

Aneurysms result from a weakness in the blood [vessel](#) wall that typically occurs where the vessel branches or bifurcates—where the vessel divides or forks into two branches. Untreated, an [aneurysm](#) can grow and

rupture. A common treatment involving the placement of tiny platinum coils into the aneurysm has limitations.

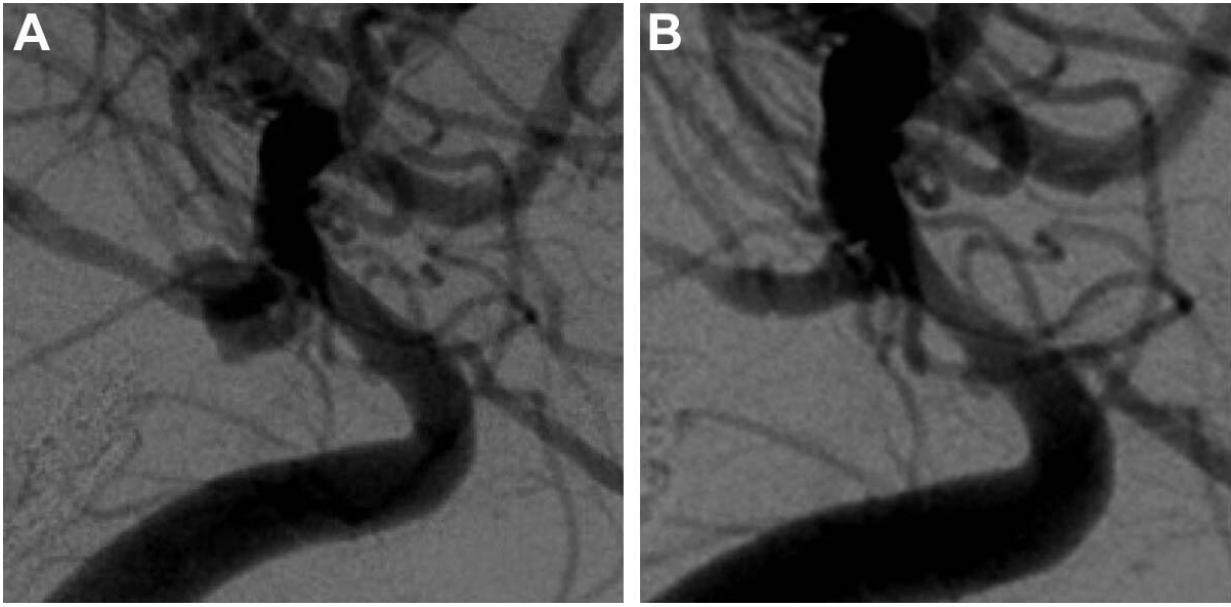
"If the aneurysm has a wide neck, the coil might fall into the blood vessel and lead to clot formation and incomplete aneurysm occlusion," said study lead author Nimer Adeeb, M.D., from the Department of Neurosurgery and Interventional Neuroradiology at Louisiana State University in Shreveport, Louisiana. "Many times, you end up putting a stent in the blood vessel to prevent the coils from falling out and to keep them compacted within the aneurysm. This can have its own complications and requires using blood thinners."

A braided wire device known as the Woven EndoBridge (WEB) was developed to overcome those limitations. The device is placed inside the aneurysm under angiographic guidance, where it causes a clot to form, closing off the aneurysm and reducing the risk of bleeding without requiring supporting stents or blood thinners.

"After you put the WEB device through the neck of the aneurysm, it opens up," Dr. Adeeb said. "Given that it's bigger than the neck of the aneurysm, it usually stays in place. One quick procedure is usually enough for successful treatment."

The U.S. Food and Drug Administration (FDA) approved the WEB device for wide-neck intracranial bifurcation [aneurysms](#). Some specialists have used it off-label for the treatment of sidewall aneurysms, a type of wide-necked aneurysm that occurs at the side of a blood vessel rather than its bifurcation tip.

Research on the WEB device's use in wide-necked sidewall aneurysms has been limited to studies with a small number of cases.



Digital subtraction angiography images show posterior communicating artery aneurysm (A) before and (B) at last follow-up after Woven EndoBridge device placement. Credit: Radiological Society of North America

For the new study, Dr. Adeeb and colleagues compared the WEB device in bifurcation and sidewall aneurysms using a [large database](#) spanning more than 10 years from the WorldWideWEB consortium, a group of 23 [academic institutions](#) in North America, South America, Australia and Europe. Dr. Adeeb co-lead the effort with Adam A. Dmytriw, M.D., from Massachusetts General Hospital in Boston.

A total of 683 intracranial aneurysms were treated using the WEB device in 671 patients. Of those, 572 were bifurcation aneurysms, and 111 were sidewall aneurysms. Propensity score matching, a way to increase the power of a study by accounting for differences in patients, resulted in 91 bifurcation and sidewall aneurysms pairs.

The complication rate was very similar between the two approaches.

"We found out that there is no significant difference using the WEB device in sidewall aneurysms compared with bifurcation aneurysms," Dr. Adeeb said. "The results show that the WEB device is safe and effective to use for sidewall aneurysms."

Dr. Adeeb hopes that the study will help drive a discussion about expanding the indications for the WEB device to include certain sidewall aneurysms.

As additional institutions continue to join the consortium, Dr. Adeeb and his colleagues are continuing the research, comparing the WEB device with other treatments for different types and locations of aneurysms. They also plan to track changes that happen to [device](#) shape and compaction over time and its relationship to aneurysm occlusion status.

"Our ultimate goal is to provide our patients with the best possible treatment for their brain aneurysms," he said.

More information: Nimer Adeeb et al, Multicenter Study for the Treatment of Sidewall versus Bifurcation Intracranial Aneurysms with Use of Woven EndoBridge (WEB), *Radiology* (2022). [DOI: 10.1148/radiol.212006](#)

Provided by Radiological Society of North America

Citation: Novel treatment effective for sidewall brain aneurysm (2022, April 19) retrieved 28 April 2024 from <https://medicalxpress.com/news/2022-04-treatment-effective-sidewall-brain-aneurysm.html>

This document is subject to copyright. Apart from any fair dealing for the purpose of private study or research, no part may be reproduced without the written permission. The content is provided for information purposes only.