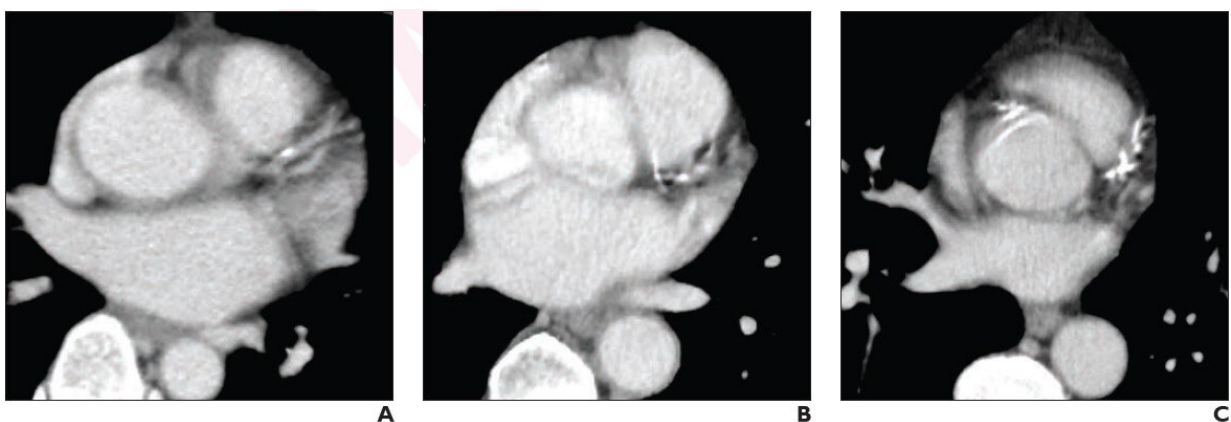


# Visual ordinal scoring of coronary artery calcium on chest CT: Diagnostic performance and prognostic utility

April 27 2022

---



(A) mild, (B) moderate, (C) severe CAC on non-gated contrast-enhanced chest CT. Credit: American Roentgen Ray Society (ARRS), *American Journal of Roentgenology (AJR)*

According to ARRS' *American Journal of Roentgenology (AJR)*, routine visual ordinal coronary artery calcium (CAC) assessment on all chest CT examinations could identify a large number of patients who might benefit from preventive therapies.

"Visual ordinal CAC assessment on both contrast-enhanced and non-contrast chest CT has high diagnostic performance, prognostic utility, and interobserver agreement," confirmed corresponding author Kate

Hanneman, MD, MPH, from Toronto General Hospital, University Health Network in Ontario.

Hanneman and colleagues' retrospective study included 260 patients (mean age, 60; 158 male, 102 female) who underwent both non-gated chest CT (contrast-enhanced in 116 patients; non-contrast in 144 patients) and cardiac calcium-score CT within a 12-month interval. A cardiothoracic radiologist visually assessed CAC on chest CT using an ordinal scale: absent, mild, moderate, or severe.

Ultimately, visual ordinal assessment of coronary artery calcium on both contrast-enhanced and non-contrast non-gated chest CT has [high sensitivity](#) (83% vs 90%,  $p=.20$ ) and specificity (100% vs 100%,  $p=.99$ ), prognostic utility (HR 4.5,  $p=.02$  and HR 3.4,  $p=.003$ , respectively), and excellent interobserver agreement ( $\kappa=0.89$  and  $\kappa=0.95$ , respectively).

"Routine reporting of CAC on all chest CT examinations regardless of clinical indication and [contrast](#) material administration could identify a large number of patients with previously unknown CAC who might benefit from preventive treatment," Dr. Hanneman added.

**More information:** Camila Urzua Fresno et al, Visual Ordinal Scoring of Coronary Artery Calcium on Contrast-Enhanced and Non-Contrast Chest CT: A Retrospective Study of Diagnostic Performance and Prognostic Utility, *American Journal of Roentgenology* (2022). [DOI: 10.2214/AJR.22.27664](https://doi.org/10.2214/AJR.22.27664)

Provided by American Roentgen Ray Society

Citation: Visual ordinal scoring of coronary artery calcium on chest CT: Diagnostic performance and prognostic utility (2022, April 27) retrieved 27 June 2024 from

<https://medicalxpress.com/news/2022-04-visual-ordinal-scoring-coronary-artery.html>

This document is subject to copyright. Apart from any fair dealing for the purpose of private study or research, no part may be reproduced without the written permission. The content is provided for information purposes only.