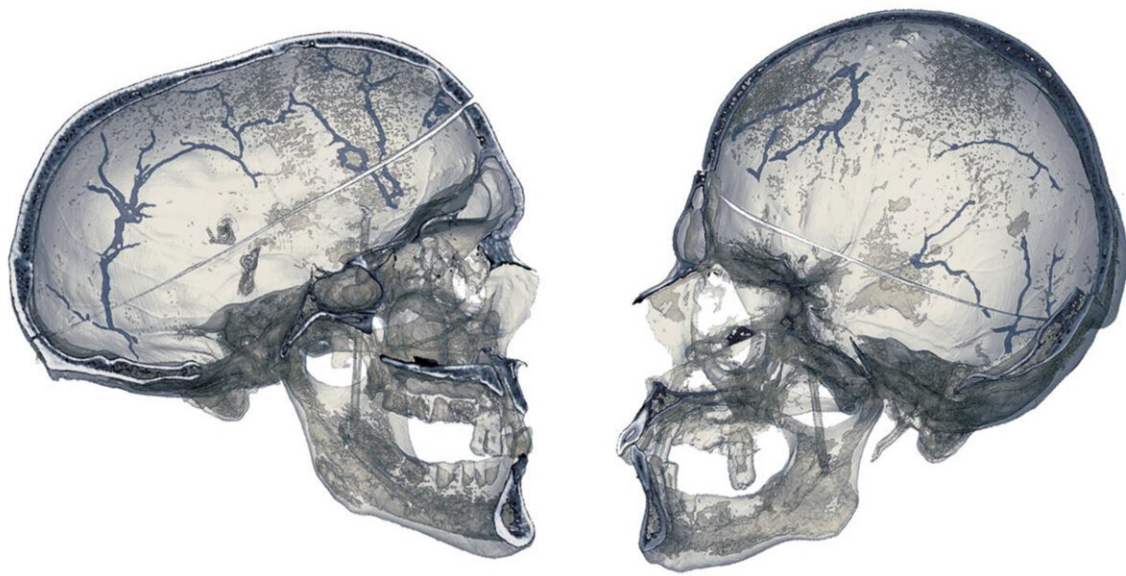


Investigating the diploic veins in skulls with premature suture fusion

September 15 2022



Diploic veins. Credit: CENIEH

The diploic veins run inside the bones of the skull and leave channels that can be studied in osteological collections, in other words, in historical populations and fossil individuals. A study, led by Stanislava Eisová and coordinated by Emiliano Bruner, who leads the Paleoneurology Group at the Centro Nacional de Investigación sobre la Evolución Humana (CENIEH), has looked at how premature fusion of the skull sutures influences the distribution of this vascular system.

The craniovascular traits are marks left by veins and arteries on the surface of or inside bones, and they enable the patterns of blood flow to be investigated in [extinct species](#) or past populations. In certain cases, they can have a functional value associated to the circulation of the blood (such as for oxygenation or thermal regulation), and in other cases they can be used as [genetic markers](#) linking individuals because they are inheritable.

The results of the new study, conducted with computerized tomography, suggest that, on average, an adult has five diploic vessels that are large (diameter of more than 1 mm), distributed fairly symmetrically between the two sides of the skull and without apparent differences that can be ascribed to age or sex.

Cranial deformation

The study also considers the effect of premature [fusion](#) of the skull (craniosynostosis) on the distribution of these vessels. Premature fusion of the sutures deforms the braincase. It reduces the diameter of the vessels in cases where the deformation leads to rounder skulls (brachycephaly), and increases their number in the anterior part of the skull (frontal bone) when the deformation produces longer skulls (dolicocephaly).

The study, published in the *Journal of Morphology*, was performed in collaboration with Charles University in Prague (Czech Republic), and it is the latest of a series of papers on the craniovascular traits in modern human populations, a series that has included analyses of the middle meningeal artery, the venous sinuses, and the venous orifices in the braincase.

"The interest of this research is not only anthropological, but also biomedical, because premature fusion of the [skull](#) sutures is a

developmental defect whose frequency is fairly high, and our data may offer useful information both for studying the vascular functions and in the clinical and surgical fields," says Bruner.

More information: Stanislava Eisová et al, Diploic vein morphology in normal and craniosynostotic adult human skulls, *Journal of Morphology* (2022). [DOI: 10.1002/jmor.21505](https://doi.org/10.1002/jmor.21505)

Provided by CENIEH

Citation: Investigating the diploic veins in skulls with premature suture fusion (2022, September 15) retrieved 25 April 2024 from <https://medicalxpress.com/news/2022-09-diploic-veins-skulls-premature-suture.html>

This document is subject to copyright. Apart from any fair dealing for the purpose of private study or research, no part may be reproduced without the written permission. The content is provided for information purposes only.