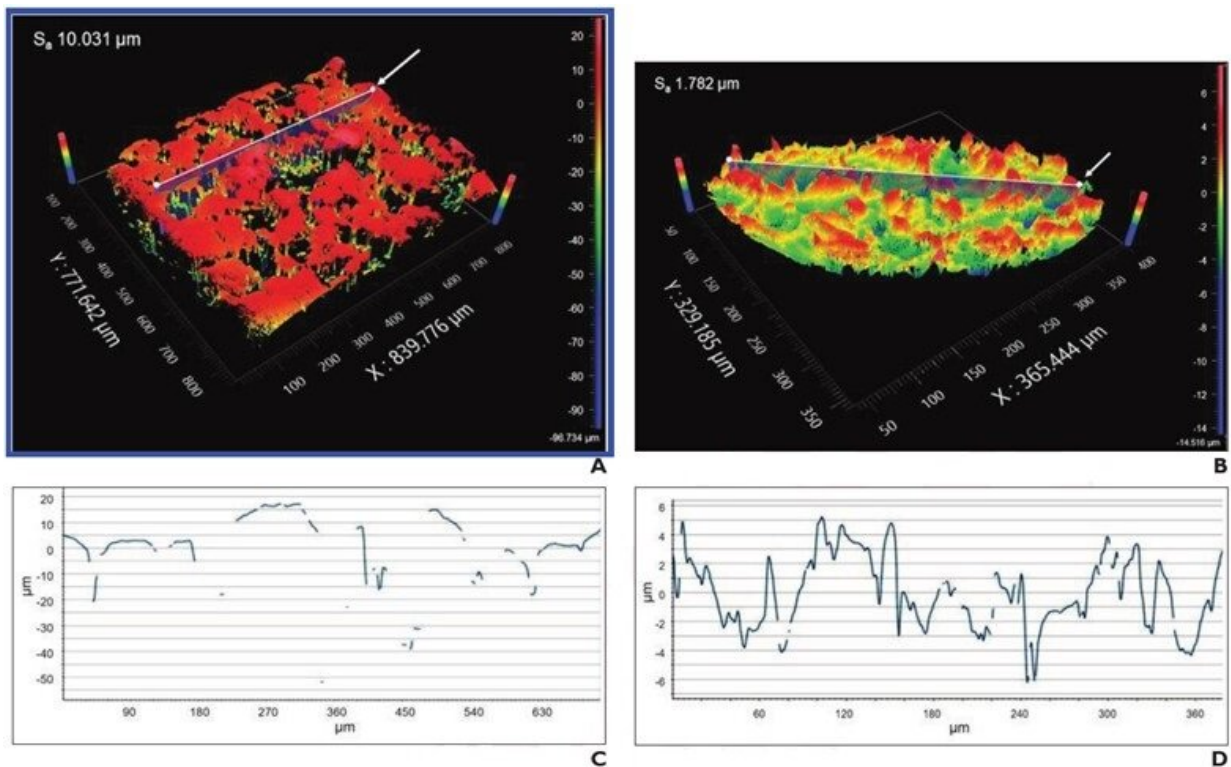


Ultrasound color Doppler twinkling in commercial breast biopsy markers

September 7 2022



Analysis performed after removing general form and waviness from imaging data. Surface relief maps of (A) Cork and (B) MRI (Flex) markers. X-Y plots of corresponding slice profile for (C) Cork and (D) MRI Flex markers. Arrow in surface relief maps shows slice location for X-Y plots. Discontinuities in curves indicate regions where light from instrument was not adequately reflected to measure surface. Credit: ARRS/AJR

According to ARRS' *American Journal of Roentgenology* (*AJR*), ultrasound color Doppler twinkling may aid the detection of certain biopsy markers in metastatic axillary nodes that resume normal morphology after neoadjuvant systemic therapy.

Noting that certain [breast biopsy](#) markers exhibited actionable twinkling (i.e., sufficient confidence to rely solely on twinkling for target localization) in cadaveric breast, "twinkling was observed with greater confidence for C1-6 and 9L than ML6-15 [transducer](#)," wrote first author Christine U. Lee, MD, Ph.D., from the department of radiology at Mayo Clinic in Rochester, MN. "Actionable twinkling was associated with higher marker surface roughness."

Dr. Lee and colleagues evaluated 35 commercial breast biopsy markers for twinkling artifact in various experimental conditions, including scanning medium (solid gel phantom, ultrasound coupling gel, cadaveric breast), transducer (ML6-15, 9L, C1-6), and embedding material (present vs. absent). Markers were then assigned twinkling scores from 0 (confident in no twinkling) to 4 (confident in exuberant twinkling); score ≥ 3 represented actionable twinkling.

Ultimately, three breast biopsy markers—Cork, Q, and MRI (Flex)—exhibited actionable ultrasound twinkling for ≥ 2 transducers in cadaveric breast. Additionally, [surface roughness](#) was significantly higher for markers with than without actionable twinkling for the C1-6 (median values: 0.97 vs 0.35, $p=.02$) and 9L (1.75 vs. 0.36; $p=.002$) transducers.

"The use of twinkling [artifact](#) to help detect biopsy markers by ultrasound could impact breast radiologists in performing preoperative localization procedures after NST," the authors of this *AJR* article concluded, thus impacting breast surgeons in performing intraoperative localization.

More information: Christine U. Lee et al, Factors Associated With Ultrasound Color Doppler Twinkling by Breast Biopsy Markers: In Vitro and Ex Vivo Evaluation of 35 Commercially Available Markers, *American Journal of Roentgenology* (2022). [DOI: 10.2214/AJR.22.28107](https://doi.org/10.2214/AJR.22.28107)

Provided by American Roentgen Ray Society

Citation: Ultrasound color Doppler twinkling in commercial breast biopsy markers (2022, September 7) retrieved 26 April 2024 from <https://medicalxpress.com/news/2022-09-ultrasound-doppler-twinkling-commercial-breast.html>

This document is subject to copyright. Apart from any fair dealing for the purpose of private study or research, no part may be reproduced without the written permission. The content is provided for information purposes only.