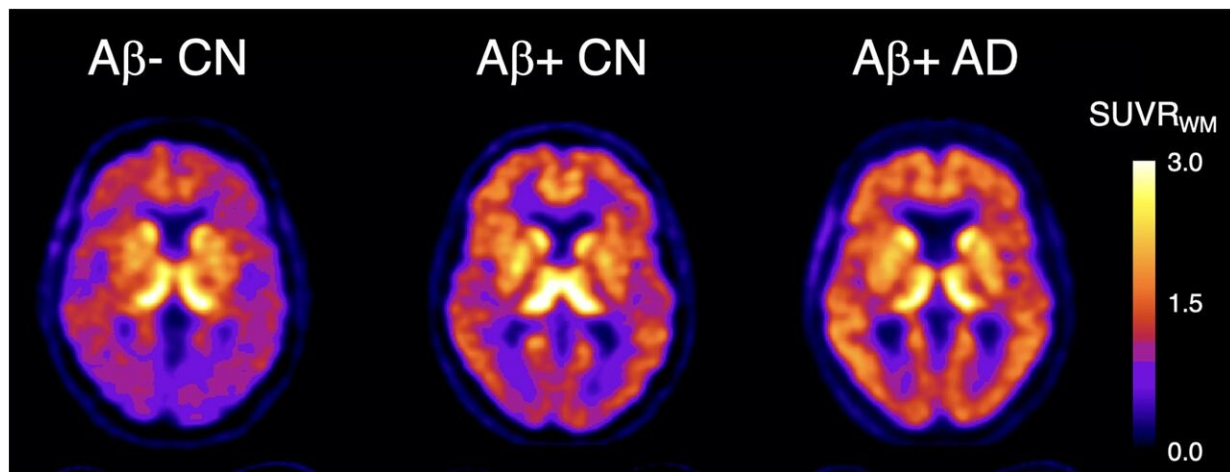


Novel PET imaging agent detects earliest signs of Alzheimer's disease

October 19 2022



Graphical abstract. ^{18}F -SMBT-1 PET studies showed that Ab+ Alzheimer's disease (AD) patients, but most importantly, Ab+ controls (CN) have significantly higher regional ^{18}F -SMBT-1 binding than Ab- CN, with ^{18}F -SMBT-1 retention highly associated with Ab burden. These findings suggest that increased ^{18}F -SMBT-1 binding is detectable at the preclinical stages of Ab accumulation. Credit: *Journal of Nuclear Medicine* (2022). DOI: 10.2967/jnumed.121.263255

A new highly selective PET imaging agent can detect the presence of overexpressed monoamine oxidase-B (MAO-B) in cognitively unimpaired individuals with high beta amyloid (Ab)—one of the earliest signs of Alzheimer's disease—according to research published in the

October issue of the *Journal of Nuclear Medicine*.

The radiotracer, ^{18}F -SMBT-1, allows for a better understanding of the role of inflammation in Alzheimer's disease, which can enable more accurate staging and prognosis at earlier stages. Brain inflammation that accompanies Alzheimer's disease involves reactive astrocytes, which are cells that overexpress MAO-B.

The newly developed ^{18}F -SMBT-1 radiotracer is highly selective for MAO-B and as a result has increased binding to reactive astrocytes. "This increased binding suggests that ^{18}F -SMBT-1 can potentially be used as a surrogate marker to detect reactive astrogliosis in Alzheimer's disease," noted Victor Villemagne, MD, professor of psychiatry at the University of Pittsburgh in Pittsburgh, Pennsylvania.

The study aimed to characterize ^{18}F -SMBT-1 binding to reactive astrocytes across the Alzheimer's disease continuum. Study participants included three clinical groups: 57 cognitively unimpaired controls, 12 subjects meeting criteria for [mild cognitive impairment](#) (MCI), and eight subjects meeting criteria for Alzheimer's disease.

Participants underwent several types of imaging, including ^{18}F -SMBT-1 PET, Ab PET, tau PET, and MRI. Images were normalized and statistical analyses conducted to assess ^{18}F -SMBT-1 binding in relation to Ab and tau pathology burden. ^{18}F -SMBT-1 was found to be highly correlated with Ab burden, and much less with tau burden.

The three clinical groups were then classified based on their Ab status (either as Ab+ or Ab-). No significant differences in ^{18}F -SMBT-1 binding were found among Ab- participants in the control and MCI groups. In the Ab+ subjects with Alzheimer's disease, ^{18}F -SMBT-1 binding was significantly higher. Most importantly, ^{18}F -SMBT-1 binding was significantly higher in the Ab+ [control group](#) as compared to Ab-

control group.

"It's of note that the [brain regions](#) where we saw this higher ^{18}F -SMBT-1 binding in the control group are regions known for early Ab deposition. This suggests that reactive astrocytes are associated with early Ab deposition at the preclinical stages of Alzheimer's disease and likely play a role over clinical progression," said Villemagne.

He continued, "Implementation of ^{18}F -SMBT-1 will clarify the role of reactive astrogliosis in neurodegenerative conditions, not just Alzheimer's disease and its potential independent and/or synergistic effects on pathology, neurodegeneration, cognition, and [disease progression](#). This has the potential to define and refine the diagnostic, staging and prognostic roles of reactive astrogliosis in these conditions."

More information: Victor L. Villemagne et al, Assessing Reactive Astrogliosis with ^{18}F -SMBT-1 Across the Alzheimer Disease Spectrum, *Journal of Nuclear Medicine* (2022). [DOI: 10.2967/jnumed.121.263255](https://doi.org/10.2967/jnumed.121.263255)

Provided by Society of Nuclear Medicine

Citation: Novel PET imaging agent detects earliest signs of Alzheimer's disease (2022, October 19) retrieved 25 April 2024 from <https://medicalxpress.com/news/2022-10-pet-imaging-agent-earliest-alzheimer.html>

<p>This document is subject to copyright. Apart from any fair dealing for the purpose of private study or research, no part may be reproduced without the written permission. The content is provided for information purposes only.</p>
